

RECONSTRUCTION OF HIT-AND-RUN VEHICLE TYPE BASED ON UN-COMMON RUN-OVER INJURIES

Vidanapathirana M¹, Gunethilake K.M.T.B.²

¹Department of Forensic Medicine, Faculty of Medical Sciences,
University of Sri Jayewardenepura, Sri Lanka and

²Office of the JMO, Provincial General Hospital, Ratnapura, Sri Lanka

ABSTRACT

The main objective of investigations in hit-and-run accidents is to trace the vehicle. This is a significant challenge when there is no eye witness. It is easy when vehicle is a car or heavy vehicle since it leaves expected injury patterns. Following case discussion is based on a body found roadside with un-common run-over injuries.

An unidentified body with injuries was found roadside in supine position. There were no eyewitnesses. Autopsy revealed three groups of injuries; crushed fractures in feet, crushed laceration over the pubic area with underlying major vessels damage, and superficial abrasions over knees. Distance from feet to knee injuries was 23 inches and to pelvic injuries 46 inches. Stomach had liquor smell.

Two areas of crushed injuries with almost injury free area in-between suggest run-over by two tires. The distance between two crush injuries was 4 feet and was compatible with rear wheels of a three-wheeler. Injuries over knees were not severe and were situated midway between two severe injuries and were compatible with front tire of three-wheeler. The deceased would have been in lying position probably under the influence of alcohol. However, there were no tire marks, paint or glass fragments etc for specific identification of the three wheeler.

Keywords: hit and run accident, un-common run-over injuries, reconstruction, three wheeler.

INTRODUCTION

Leaving the scene of a crash without reporting is called hit-and-run collisions. It is an offence in most countries¹ including Sri Lanka. Hit-and-run collision is a punishable offence as it delays crash notification thereby delaying emergency response which increases the likelihood of traffic fatality². Therefore, hit-and-run crashes account for a significant proportion of pedestrian fatalities. Of the 48,000 pedestrian deaths that were recorded in the United States between 1998 and 2007, 18.1% were caused by hit-and-run crashes³.

Many studies have been devoted to improve the ways and means to identify hit-and-run vehicles and the drivers involved. A study done in Singapore in 2008 found that drivers were more likely to run when crashes occurred at night, on a bridge and flyover, bend, straight road and near shop houses; involved two vehicles, two-wheel vehicles and vehicles from neighboring countries; and when the driver was a male, minority, and aged between 45 and 69¹. On the other hand, collisions occurring on undivided roads were less likely to be hit-and-run crashes¹.

The main objective of the medico-legal investigations in hit-and-run accidents is to trace the vehicle. This is a significant challenge when there is no eye witness. It is easy when the vehicle is a car or heavy vehicle since it leaves expected injury patterns. Following case discussion is based on a body found roadside with un-common run-over injuries.

Case report

An unidentified body with injuries was found in the dawn, in a pool of blood at the roadside along a main road in front of a bus halt in supine position with the head directed towards the pavement. According to the investigating police officer, there were no eyewitnesses.

Autopsy revealed that the body was clad in a sarong and a long sleeved shirt and the clothes had dust and mud stains but no tire marks. There were no paint or glass fragments in the clothes and the body. There were three groups of injuries (Figure 1); transversely placed crushed lacerations and underlying fractures in feet (Figure 2), almost transversely placed elongated large

crushed laceration over the pubic area of the pelvis with underlying major vessels damage including right femoral vessels. (Figure 3), and superficial abrasions over knees (Figure 4). Distance from feet to knee injuries was 23 inches and to pelvic injuries 46 inches.

Except for pallor, the remaining internal organs were unremarkable. Stomach had liquor smell but blood alcohol level was not available due to leakage of the sample while transporting to the laboratory or during storage at the Laboratory.

Cause of death was haemorrhagic shock due to major pelvic vessels damage due to blunt force trauma. Further, it was noted that the injury pattern was consisted with run-over injuries.

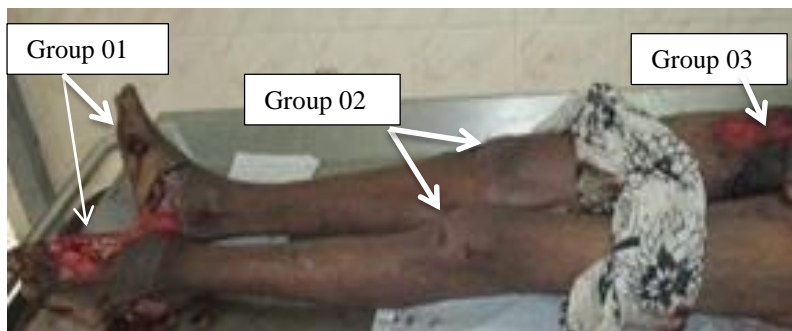


Figure 1: Three groups of injuries

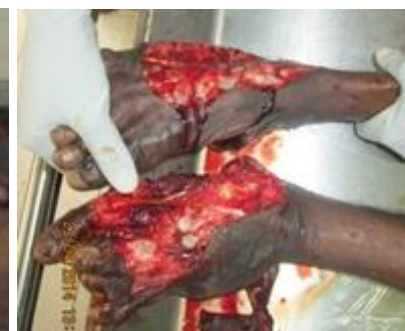

Figure 2: Crushed feet

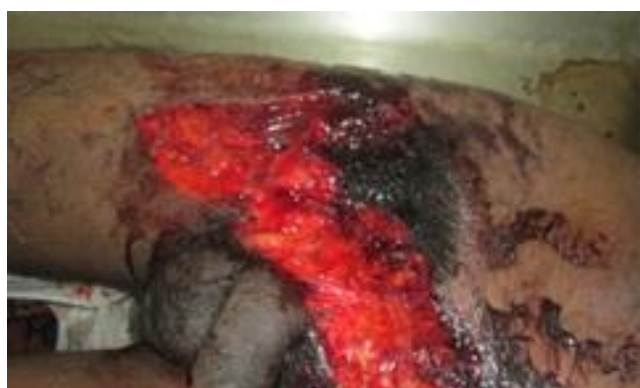

Figure 3: Crushed laceration over the pelvis

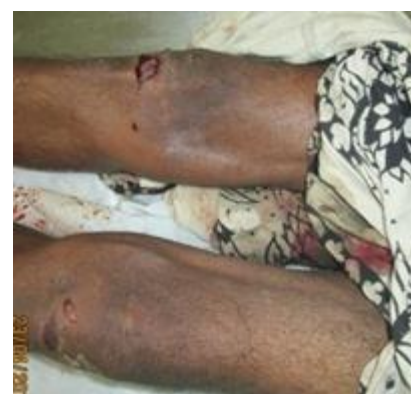

Figure 4: Superficial injuries on knees

DISCUSSION

Many pedestrians who are involved in road traffic accident die as a result of the driver leaving the pedestrian who is struck unattended at the scene of the accident⁴. Similar to scene of crime findings of this case, being a fatal accident, nighttime condition, and straight and flat road section significantly increase the likelihood that the vehicle driver would leave the scene after hitting a pedestrian⁴.

There were no injuries or injury patterns that were compatible with 'primary impacts' such as bumper fractures, patterned injuries etc, 'secondary impacts' such as glass cuts etc or 'secondary injuries' such as grazed abrasions to suggest that the pedestrian was in standing or squatting position at the time of the impact.

Two areas of crush injuries placed transversely over feet and pelvis with almost injury free area in-between suggest run-over by two tires. Therefore, run over by a motor bike could be safely excluded.

The distance between the two crushed injuries was 4 feet and it suggests that the offending vehicle could be a less wide vehicle rather than a van or standard compact car where the width is usually about 5.6 feet⁵. The distance between the rear wheels of a standard three wheeler available in Sri Lanka is 4 feet.

Absence of underlying pelvic fractures or severe internal organ damages were more compatible with wheels of a light vehicle such as three-wheeler rather than a supermini, subcompact⁵ or light car such as Maruti 800 where the width of wheels is about 4 and half feet (56 inches)⁵.

Injuries over knees were not severe and were situated midway between the two severe injuries and were compatible with front tire of a three-wheeler. Less severe injuries by

front tire could be due to less weight exerted on it.

Absence of injuries to suggest that the pedestrian was in standing or squatting position at the time of the impact, presence of liquor smell in stomach and presence of injuries compatible with run-over suggest that the deceased would have been in lying position probably under the influence of alcohol.

In run over, tire tread marks do not invariably occur, but if they do, it may be on the clothing and or on the skin⁷. In this case, except dust and mud stains, no tire marks were found in clothes and the clothes may have prevented tire marks on the skin too. The absence of injuries on the rest of the body should be due to the clearance space of the vehicle from floor and it is 9"-14" in a standard three-wheeler.

However, no paint or glass fragments on the body were found for further confirmation and specific identification of the vehicle.

Low speed vehicle run-over (LSVRO) incidents are those where a pedestrian, is injured or killed by a slow moving vehicle (less than 30 km/hr or 19 mph) in both traffic and non-traffic area⁸. Three-wheeler is a moderate speed vehicle and it also can cause low speed vehicle run-over (LSVRO) deaths.

Integrating median separation and speed humps into road design and construction and installing street lights will help to curb the problem of pedestrian hit-and-run accidents⁴. In addition, targeted traffic enforcement should be performed on weekends and nighttime². However, the effects of road-related factors and harsher legal punishments have limited influence for reducing hit-and-run likelihood after a driver hits a pedestrian⁹.

However, to initiate the prosecution procedures, the specific identification of the vehicle is a basic requirement. Therefore, the

reconstruction of the event in order to identify the vehicle in hit-and-run crashes by the forensic pathologist is highly important.

CONCLUSION

The injury pattern was compatible with run-over by a three-wheeler while victim in lying position. However, there was no autopsy evidence for the specific identification of the offending vehicle.

REFERENCES

1. Tay R¹, Rifaat SM, Chin HC. A logistic model of the effects of roadway, environmental, vehicle, crash and driver characteristics on hit-and-run crashes. Accident; Analysis and Prevention. 2008 Jul;40(4):1330-6. doi: 10.1016/j.aap.2008.02.003.
2. Tay R, Barua U, Kattan L. Factors contributing to hit-and-run in fatal crashes. Accident; Analysis and Prevention. 2009 Mar;41(2):227-33. doi: 10.1016/j.aap.2008.11.002.
3. MacLeod KE, Griswold JB, Arnold LS, Ragland DR. Factors associated with hit-and-run pedestrian fatalities and driver identification. Accident; Analysis and Prevention. 2012 Mar;45:366-72. doi: 10.1016/j.aap.2011.08.001.
4. Aidoo EN, Amoh-Gyimah R, Ackaah W. The effect of road and environmental characteristics on pedestrian hit-and-run accidents in Ghana. Accident; Analysis and Prevention. 2013 Apr;53:23-7. doi: 10.1016/j.aap.2012.12.021.
5. Subcompact cars. https://en.wikipedia.org/wiki/Subcompact_car. Accessed on 07.11.2015
6. Maruti 800. https://en.wikipedia.org/wiki/Maruti_800. Accessed 04.11.2015.
7. Dimaio VJ, Dimaio D, Deaths caused by motor vehicle accidents, Forensic Pathology, 2nd Ed, CRC press, Florida, 2000, 313.
8. CCYPCG: Annual Report Deaths of Children and young people. Brisbane, Australia: Commission for children and young people and child guardian; 2005.
9. Fujita G, Okamura K, Kihira M, Kosugge R. Factors contributing to driver choice after hitting a pedestrian in Japan. Accident; Analysis and Prevention. 2014 Nov;72:277-86. doi: 10.1016/j.aap.2014.07.002.