

AN UNUSUAL CASE OF INFANTICIDE BY INTERNAL COMPRESSION OF AIRWAYS - A CASE REPORT -

Rohan Ruwanpura¹, Sriyantha Amararatne² & Kumudu Dhahanayake²

¹Consultant Judicial Medical Officer, Teaching Hospital, Karapitiya, Galle, Sri Lanka

²Registrar in Forensic Medicine

ABSTRACT

In Sri Lanka, as in many other jurisdictions, infanticide refers to killing of a newborn below 12 months in age, by his biological mother. Methods used in infant homicides range in a vast spectrum, including acts of omissions, asphyxia, poisoning, drowning, suffocation, and sharp and blunt force injuries etc. Internal examination revealed a “Suraya” [a cylindrical metallic object around 1cm in diameter and 5cm in length, which is used as a protective agent from evil omens] passed into the mid third of the oesophagus. The cause of death is attributed to compression of respiratory tracts due to foreign body in the oesophagus. The mother of the infant is a known psychiatric patient since six months prior to the incident.

INTRODUCTION

Infanticide is one of the rarer, but well known, oldest medico legal entities heard from all parts of the world^{1,2}. As in many jurisdictions, infanticide in Sri Lanka refers to killing of a newborn below 12 months in age. The infant killing by the mother is exempted from culpable homicide amounting to murder by provisions in the criminal laws of Sri Lanka³. Methods used in infant homicides range in a vast spectrum, including acts of omissions, asphyxia, poisoning, drowning, suffocation, and sharp and blunt force injuries etc. The present case is about infanticide due to compression of the respiratory passages by passing metallic object into the oesophagus by a mentally subnormal mother.

Case history

A body of a female infant, two months in age, was referred to the medico legal unit of the

Karapitiya Teaching Hospital after unsuccessful resuscitation attempts of artificial ventilation and cardiac stimulation at the emergency therapy unit. According to grandmother of the victim, the incident took place at their residence, around the mid night. While approaching child's bedroom in response to abnormal gurgling noise, she noticed that the victim was lying on its back on the bed, markedly bluish and dyspnoeic. The mother of the infant gave no detailed explanation to what has happened, but stated that both herself and her child were attacked by an evil spirit. She is a known psychiatric patient since last six months prior to the incident, but she rapidly recovered in response to treatment with antipsychotic drugs and rational until childbirth and her condition was again deteriorating during past two weeks. The relatives were under the impression that recurrence of her illness is due to influence of the evil spirit of her husband's father who died around the said period⁴. They have approached an indigenous spiritual healer who provided them with protective “Suyraya” [thailsmans] for both mother and the child.

Autopsy

The body was that of an infant of 8 weeks in age and of good nourishment, 64 cm in length, 2800g in weight. There were no external injuries; finger tips showed marked cyanosis and no subconjunctival or mucosal petechial haemorrhages were noted. Internal examination revealed a “Thalisman” [cylindrical metallic object around 1 cm in diameter and 5 cm in length, which is used as a protective agent against harmful evils] passed into mid third of the oesophagus. The mucosal tissues in the throat region were slightly eroded and swollen. The foreign object was situated beneath the bifurcation of trachea which was compressed. A

small amount of emulciated milk was present in the stomach. A few subepicardial and subpleural petechial haemorrhages with bilateral pulmonary oedema were noted. All other organs were unremarkable. The cause of death is attributed to compression of respiratory passages due to foreign body in the oesophagus.

DISCUSSION

The infanticide is rare but considered being a serious crime, which shows a decreasing trend in developed countries⁵. Killing of an infant is not a difficult task which can be performed even by a trivial act of omission or commission. It appears that, the most likely intention of the assailant was to obstruct the airways by passing foreign body into the larynx, but it has slipped into the oesophageal opening probably due to action of the epiglottis and concave of posterior wall of the mouth. Although passing a small foreign object through oesophagus is not always fatal, the length and stiffness of the object like "Suraya", causes it to be stuck at the level of tracheal bifurcation, applying pressure on the respiratory passages^{6,7}. The compression tracheo-oesophageal membrane causes mechanical obstruction of the airways as well as sudden cardiac inhibition due to stimulation of parasympathetic receptors. Cardiac inhibition⁸ is the most frequent mode of death in gagging and choking⁹.

According to Adelson, the infanticide must be proven beyond possible rather reasonable doubt. It is obvious in this case that an accidental swallowing of a foreign body by two months old infant is impossible. In fact, aspirations and ingestion of foreign bodies are noted in young children who were likely victims of physical child abuse¹⁰. The exclusion of sudden infant death¹¹ is an essential proof needed in all cases of infant deaths and, therefore, all infant deaths require in thorough autopsy examination with application of special dissecting techniques¹². However, autopsy findings of this case are self explanatory and exclusive of any natural or unforeseen event.

Infanticide is often associated with an acute and a chronic structured psychiatric conditions such as puerperal psychosis, maniac-depressive

psychosis, schizophrenia, epilepsy, substance abuse, etc. Sometimes, it is connected to socio-cultural constraints and confusions of adaptation of the postpartum stage¹³. The presence of genetic determinants in potential cases of maternal infanticide has already been confirmed¹⁴. An assailant of this case is a known psychiatric patient, who was apparently mismanaged by the relatives during her perinatal period. Approaching native healers in management of psychiatric patients, especially in post partum psychosis, is still heard from time to time in rural areas of Sri Lanka¹⁵. As majority cases are of a mild nature, psychiatric symptoms of which may disappear with the time without any treatment, the credit of cure goes to the native healers, convincing more and more people to obtain their services. Majority medical and legal experts support the position that a woman with postpartum psychosis who commits infanticide needs treatment rather than punishment and that appropriate treatment will deter her from killing again¹⁶.

CONCLUSIONS

The clinico-pathological aspects of an uncommon case of infanticide are discussed. The danger of avoiding or delaying in treatment of post-partum psychosis is highlighted by quoting relevant literature sources.

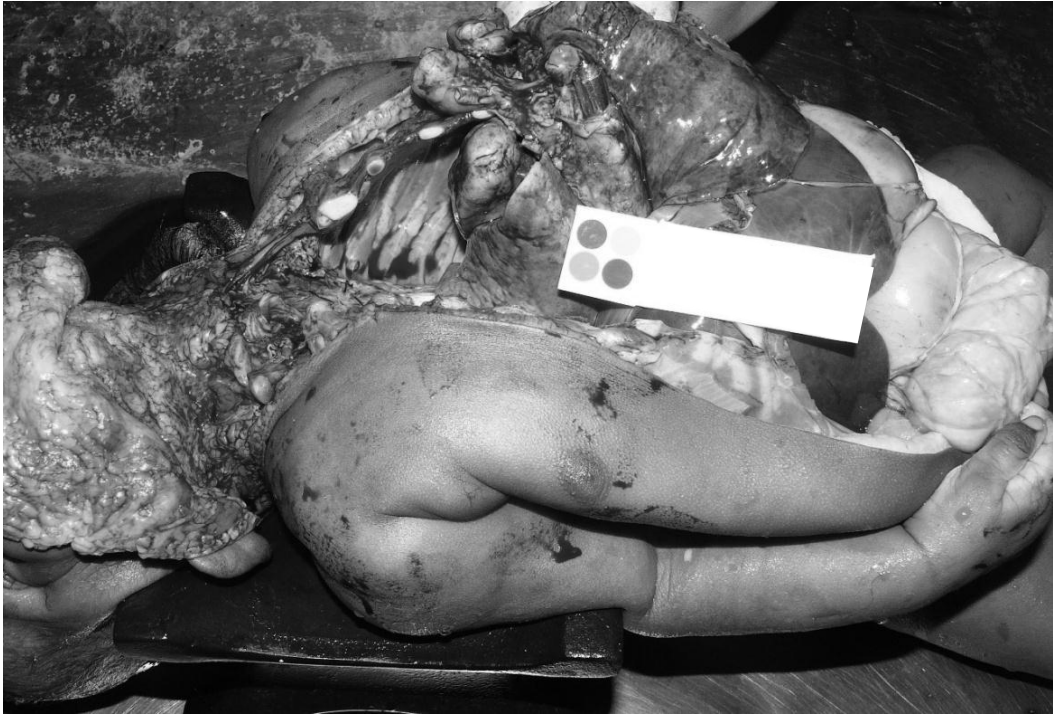

Fig 1: An oesophagus is cut open to show foreign bogy in mid third.




Fig 2: A "Suraya" [Thalisman] with a cotton string.

REFERENCES

1. Trautmann-Villalba P, Hornstein C. Children murdered by their mothers in the postpartum period *Nervenarzt*. 2007;78(11):1290-5.
2. Kociumbas J. *Gend Hist*. Azaria's antecedents: stereotyping infanticide in late nineteenth-century Australia. 2001;13(1):138-60.
3. Penal code section 383 – a. 1995; Parliament of Sri Lanka.
4. Castillo RJ. Spirit possession in South Asia, dissociation or hysteria? Part 2: Case histories *Culture, Medicine and Psychiatry* 1994(18);2:141-21.
5. Christiansen S, Rollmann D, Leth PM, Thomsen JL. Children as victims of homicide 1972-2005. *Ugeskr Laeger*. 2007;169(47):4070-4.
6. Chen X, Milkovich S, Stool D, van As AB, Reilly J, Rider G. Pediatric coin ingestion and aspiration. *Int J Pediatr Otorhinolaryngol*. 2006;70(2):325-9.
7. Rider G, Wilson CL. Small parts aspiration, ingestion, and choking in small children: findings of the small parts research project. *Risk Anal*. 1996;16(3):321-30.
8. Villain E. cardiac syncope in children. *Arch Pediatr*. 2004;11(2):169-74.
9. Baker SP, Fisher RS. Childhood asphyxiation by choking or suffocation. *JAMA*. 1980;244(12):1343-6.
10. Krugman SD, Lantz PE, Sinal S, De Jong AR, Coffman K. Forced suffocation of infants with baby wipes: a previously undescribed form of child abuse. *Child Abuse Negl*. 2007 Jun;31(6):615-21.
11. Hässler F, Zamorski H, Weirich S. The problem of differentiating between sudden infant death syndrome, fatal Munchausen's syndrome by proxy, and infanticide *Z Kinder Jugendpsychiatr Psychother*. 2007;35(4):237-44; quiz 245-6.
12. Dufková J. Autopsy technique and basic legal aspects of autopsy *Beitr Gerichtl Med*. 1990;48:93-101.
13. Rammouz I, Tahiri DA, Aalouane R, Kjjiri S, Belhous A, Ktiouet JE, Sekkat FZ. Encephale. Infanticide in the postpartum period: about a clinical case. 2008;34(3):284-288.
14. Quilter CR, Gilbert CL, Oliver GL, Jafer O, Furlong RA, Blott SC, Wilson AE, Sargent CA, Mileham A, Affara NA. Gene expression profiling in porcine maternal infanticide: A model for puerperal psychosis. *Am J Med Genet B Neuropsychiatr Genet*. 2008 Mar 24. [Epub ahead of print]
15. Amarasingham LR. Movement among healers in Sri Lanka: A case study of a sinhalese patient. *Culture, Medicine and Psychiatry* 1980 (4);1:71-20.
16. Spinelli MG. Maternal infanticide associated with mental illness: prevention and the promise of saved lives. *Am J Psychiatry* 2004;161(9):1548-57.