

DOI: <http://doi.org/10.4038/sljfmsl.v10i1.7820>

BASAL SKULL FRACTURE OF NON- TRAUMATIC ORIGIN - A CASE REPORT

Vadysinghe A.N, Gayathree T.H.I, Madarasinghe D.S & Siddique M.S

Department of Forensic Medicine, Faculty of Medicine, University of Peradeniya, Sri Lanka

Corresponding Author: Vadysinghe A.N

Email: amal_vadysinghe@yahoo.com

 <https://orcid.org/0000-0002-1994-7830>

Introduction

The Interpretation of postmortem findings is based on internal and external examination of the dead body. Postmortem artifacts (PA) are changes/ features introduced after death that may be confused with features introduced ante mortem.

We report a base of skull fracture in an extensively burnt body which was identified as a PA. This has not been reported in the literature.

Case report

A 58 -year old female was admitted to the emergency unit with extensive burns in a semiconscious state and died on the fourth day after admission.

Burns involving approximately 60% of body surface were identified at autopsy. There was a linear, almost hinged fracture in the middle cranial fossa which was identified during the removal of vault of skull. Absence of bleeding around the fracture site, absence of soft tissue injuries of the head, face and rest of the body, normal brain and pattern of skull fracture confirmed that the fracture is of postmortem origin, which may have been caused during sawing and removal of vault of skull. Further, it was identified that the thickness of the skull was less than normal which may have contributed to this.

Conclusion

This case highlights the fact that basal skull fractures may occur as an autopsy artifact. Therefore accurate interpretation of such fractures is essential to ascertain the cause and manner of death.

Keywords: Postmortem artifact, autopsy artifact, basal skull fracture, hinged fracture, burns
Manuscript



All articles in Sri Lanka Journal of Forensic Medicine, Science & Law are licensed under the terms of the Creative Commons Attribution-Non Commercial 4.0 International License

Introduction

The forensic pathologist plays a key role in the investigation of deaths. Their autopsy finding in conjunction with circumstantial evidence leads to formulating an opinion on the cause and manner of death.¹

Therefore identification and interpretation of findings autopsy is vital. Postmortem artifacts (PA) are changes/ features introduced after death that may be confused with features introduced antemortem.² PA can be introduced between death and autopsy or during the autopsy.³

We report a base of skull fracture in an extensively burnt body which was identified as a PA. This has not been reported in the literature.

Case report

A 58 -year old female admitted to the emergency unit with extensive burns in a semiconscious state died on the fourth day while being treated in the intensive care unit.

The victim was married and had no children. The husband was a farmer. She had no history of any other disease conditions and was not on any medications. However it was revealed that the deceased was distressed about her subfertility and alcohol abuse of her husband. Even though there had been suicidal ideation frequently in the recent past, there was no past history of attempted suicide. She did not take any medication or follow-up for her suicidal ideation.

History revealed that on this particular day, neighbors detected smoke and heard screams of a female from the backyard of the house. On arrival they saw that the house was on fire

and that she was locked in a room. Once rescued she had stated that she wanted to die and set herself on fire with kerosene. The empty kerosene bottle was found in the room.

The body was preserved in a refrigerator till autopsy. The autopsy commenced approximately 14 hours after death. The autopsy was of a 72 kg Asian Caucasoid 172cm in height. She was covered with white hospital cloth. There was no evidence of physical or congenital deformities. Surgical dressing was draped over the burns and was stained with yellowish green slough which emanated an offensive smell. These burns were seen on head and face, front of neck, trunk and limbs involving 60% of body surface area. The burns were both superficial and deep partial thickness in nature.

A linear, almost hinged, fracture was seen in the middle cranial fossa (Fig-1) while removing the vault of skull. There was no macroscopic or microscopic evidence of periosteal bleeding or collected blood adjacent to the fracture. This fracture extended to the temporoparietal area bilaterally up to the incision which was made to remove the vault during autopsy. There was no blood collected between meninges and the brain was normal. No injuries were identified on soft tissue of head, face or rest of the body. It was identified that the thickness of the skull was less than normal.

The cause of death was determined as septicaemia following extensive suicidal burns.

Discussion

Correct identification of postmortem artifacts are vital. The chance of misinterpretation of such PA is approximately 8% in medicolegal autopsies and higher in decomposed bodies.⁴

PA encompass minor to gross change including fractures. ¹Skeletal injury is explained as damage to a bone following an impact.^{5, 6} Injuries to bone are categorized as those are caused by blunt or sharp forces or, low/ high velocity projectiles.⁷

Skull fractures are classified based on location, type of force or type of fracture or even according to the manner of causation. ^{1, 8}

The time of infliction of a fracture is medicolegally relevant. It may cause at antemortem, postmortem or perimortem. ^{8, 9, 10}

Skull fractures are important as the skull is the protective covering of the brain. ¹¹ It is further important to determine the cause and the manner of death during the medicolegal investigation.

The mechanism of skull fractures is influenced by four variables: (a) impact velocity, (b) impact surface, (c) cortical thickness, and (d) cortical density.¹² About 70% of skull fractures are linear.¹³ The base of skull is a weak structure due to it being composed of relatively thin bone, union of multiple bones, presence of orifices (for blood vessels and nerves), sinuses and buttresses. ^{2, 14, 15}

A hinge fracture is a type of basilar fracture which is rarely seen.^{2, 16} It is a fracture placed transversely across the dorsum sellae of the skull which may appear as two halves and is due to compressive force^{1, 14, 17} It can be caused by heavy blunt force or ballistic trauma to lateral aspect of the head or substantial force to forehead or chin. ^{18, 19, 20} However this case revealed no injuries to head or face.

Furthermore thinning of skull bone was identified in this case for which no reason could be identified even though many causes have been identified in the literature. ^{21, 22, 23}

The site of initiation of skull fracture with impact is still a questionable area in forensic practice ²⁴ for which many different hypotheses have been proposed. ^{24, 25, 26, 27, 28} A fracture may be initiated towards the impact or away from the impact or at the site of the impact ^{24, 25, 26, 27, 28, 29} However no such impact was identified on head or face at autopsy in our case. The hinge fracture identified terminated on either side at temporoparietal area of the skull on the incision made for removal skull vault. This is again complies with the ‘Puppe’ rule³⁰. It is strongly indicated that it occurred after the incision for removal of the vault was made as an autopsy artifact.

Hinge fractures are rarely observed postmortem due to lack of collagen tissues in the bones due to putrefaction.⁷ However, this autopsy was done soon after death on a refrigerated body and therefore it is unlikely that the collagen content of bones were affected.

Microscopic examination of hinge fracture did not reveal any hemorrhage or tissue reaction which further confirms that the fracture was inflicted postmortem. ^{31, 32}

Approximately 180,000 burn fatalities are seen annually which predominantly occur in low and middle income countries.³³ Burn is a common type of injury in forensic practice and its incidence follows traffic injuries, falls and interpersonal violence.³⁴ Sepsis following burns is a known and common fatal complication which is evident in this case^{35, 36}

The commonest agent used in suicides or attempted suicides by burning is flame. This victim also used a flame to terminate her life.³⁷ Female gender predominance is seen in previous studies of deaths due to burns and this finding is consistent with our case.^{38, 39, 40, 41}

Conclusion

This case highlights the fact that basal skull fractures may occur during dissection of the skull as an autopsy artifact. Therefore correct interpretation is vital to ascertain cause and manner of death. It is recommended that direct supervision by a forensic pathologist during autopsy would minimize its occurrence and help interpret artifacts accurately.

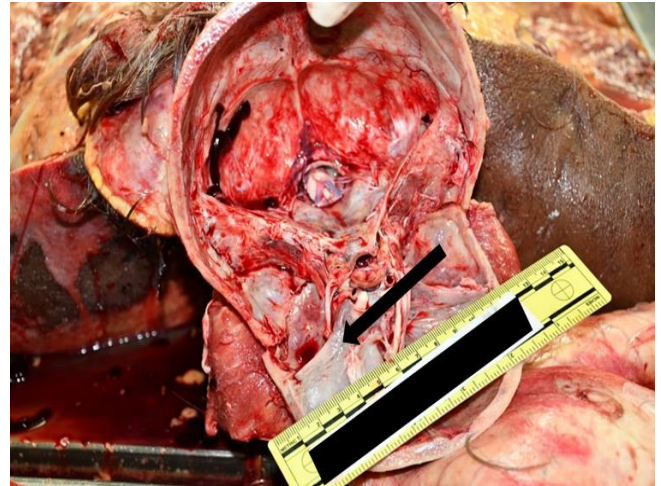


Figure 2: Hinge fracture (Indicated by arrow)

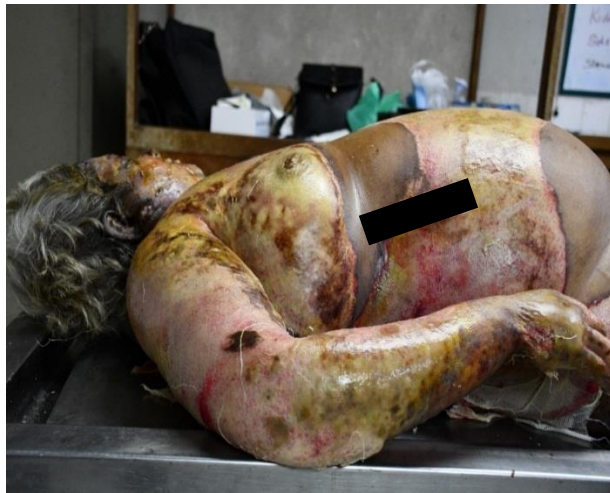

Figure 1: Extensive burns with yellow-greenish slough (severely infected)

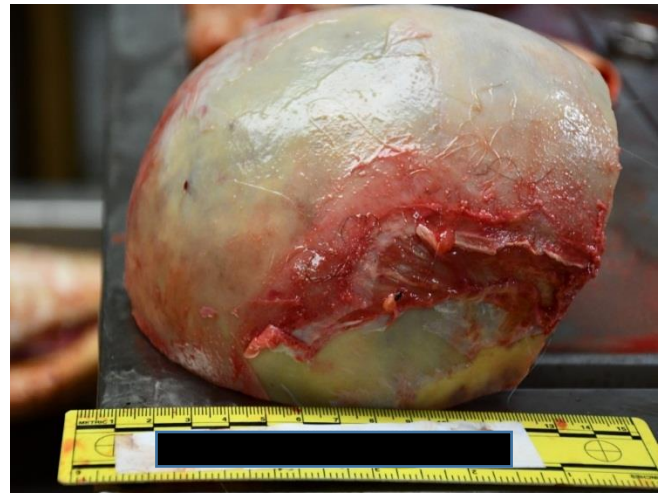

Figure 3: Skull cap. Absence of continuation hinge fracture.

References

1. Spitz WU, Spitz DJ, Fisher RS, editors. Spitz and Fisher's medicolegal investigation of death: guidelines for the application of pathology to crime investigation. Charles C Thomas Publisher; 2006.
2. Saukko P, Knight B. Head and Spinal Injuries. In: Bureau S, Ueberberg A, editors. Knight's Forensic Pathology. 3rd ed. London: Arnold Hodder headline group; 2004. p. 174-88.
3. Mason JK, Smith AM. Butterworths Medico-legal encyclopaedia. Butterworths; 1987.
4. Sauvageau A, Racette S. Postmortem changes mistaken for traumatic lesions: a highly prevalent reason for coroner's autopsy request. The American journal of forensic medicine and pathology. 2008 Jun 1; 29(2):145-7.
10.1097/PAF.0b013e318174f0d0
5. Davidson K, Davies C, Randolph-Quinney P. Skeletal trauma. In: Black S, Ferguson E, editors. Forensic Anthropology. London: CRC Press; 2011; p. 183-235.
6. Symes SA, Ericka N, L'Abbé EN, Wolff I, Dirkmaat DC. Bone in medicolegal investigations. A companion to forensic anthropology. 2012 Mar 19;10:340.DOI:10.1002/9781118255377
7. Blau S. How traumatic: a review of the role of the forensic anthropologist in the examination and interpretation of skeletal trauma. Australian journal of forensic sciences. 2017 May 4;49(3):261-80.
<https://doi.org/10.1080/00450618.2016.1153715>
8. Kranioti E. Forensic investigation of cranial injuries due to blunt force trauma: current best practice. Research and Reports in Forensic Medical Science. 2015 Oct 6;5:25-37.
<https://doi.org/10.2147/RRFMS.S70423>
9. Sauer NJ. The timing of injuries and manner of death: distinguishing among antemortem, perimortem and postmortem trauma. Forensic osteology: advances in the identification of human remains. 1998:321-32.
10. Rodríguez-Martín C. Identification and differential diagnosis of traumatic lesions of the skeleton. In Forensic Anthropology and Medicine 2006 (pp. 197-221). Humana Press. DOI:https://doi.org/10.1007/978-1-59745-099-7_8
11. Oehmichen M, Auer RN, König HG. Forensic neuropathology and associated neurology. Springer Science & Business Media; 2006 Jan 16.
12. Sioutas G, Karakasi MV, Kapetanakis S, Pavlidis P. Death due to fracture of thin calvarial bones after a fall: A forensic approach. Chinese journal of traumatology. 2017 Jun 1;20(3):180-2.

- <https://doi.org/10.1016/j.cjtee.2017.01.003>
13. Reddy KSN. The Essentials of Forensic Medicine and Toxicology. 29th ed. Hyderabad: K. Suguna Devi; 2010. p.218-38.
 14. DiMaio VJ, DiMaio D. Forensic pathology. CRC press; 2001 Jun 28.
 15. Berryman HE, Symes SA. Recognizing gunshot and blunt cranial trauma through fracture interpretation. Forensic osteology: advances in the identification of human remains. 1998;2.
 16. Hart GO. Fracture pattern interpretation in the skull: differentiating blunt force from ballistics trauma using concentric fractures. Journal of Forensic Science. 2005 Aug 31;50(6):JFS2004219-6. DOI: 10.1520/JFS2004219
 17. Moritz AR. The pathology of trauma. Lea & Febiger; 1954..
 18. DiMaio VJM, Dana SE. Blunt Force Injury. In: Froede RC, editor. Handbook of Forensic Pathology. 2nd ed. New York: CRC press Taylor and Francis Group; 2007. p. 73-104.
 19. Ferrer E, de Notaris M. Contemporary Skull Fractures: Unusual Everted Fracture. World neurosurgery. 2011;5(76):417-8. <http://dx.doi.org/10.1016%2Fj.wneu.2011.01.039>
 20. McELHANEY JH, HOPPER JR RH, NIGHTINGALE RW, Myers BS. Mechanisms of basilar skull fracture. Journal of neurotrauma. 1995 Aug;12(4):669-78. <https://doi.org/10.1089/neu.1995.12.669>
 21. Moreira-Gonzalez A, Papay FE, Zins JE. Calvarial thickness and its relation to cranial bone harvest. Plastic and reconstructive surgery. 2006 May 1;117(6):1964-71. doi: 10.1097/01.prs.0000209933.78532.a7
 22. Tsutsumi S, Yasumoto Y, Ito M. Idiopathic calvarial thinning. Neurologia medico-chirurgica. 2008;48(6):275-8. <https://doi.org/10.2176/nmc.48.275>
 23. Lo CP, Chen CY, Chin SC, Juan CJ, Hsueh CJ, Chen A. Disappearing calvarium in Gorham disease: MR imaging characteristics with pathologic correlation. American journal of neuroradiology. 2004 Mar 1;25(3):415-8.
 24. Baumer TG, Passalacqua NV, Powell BJ, Newberry WN, Fenton TW, Haut RC. Age-dependent fracture characteristics of rigid and compliant surface impacts on the infant skull—a porcine model. Journal of forensic sciences. 2010 Jul;55(4):993-7. <https://doi.org/10.1111/j.1556-4029.2010.01391.x>
 25. Gurdjian ES, Webster JE, Lissner HR. The mechanism of skull fracture. Radiology. 1950 Mar;54(3):313-39. <https://doi.org/10.1148/54.3.313>

26. Delye H, Verschueren P, Depreitere B, Verpoest I, Berckmans D, Vander Sloten J, Van Der Perre G, Goffin J. Biomechanics of frontal skull fracture. *Journal of neurotrauma*. 2007 Oct 1;24(10):1576-86. <https://doi.org/10.1089/neu.2007.0283>
27. Nahum AM, Gatts JD, Gadd CW, Danforth J. Impact tolerance of the skull and face. *SAE Technical Paper*; 1968 Feb 1. <https://doi.org/10.4271/680785>
28. Powell BJ, Passalacqua NV, Fenton TW, Haut RC. Fracture characteristics of entrapped head impacts versus controlled head drops in infant porcine specimens. *Journal of forensic sciences*. 2013 May;58(3):678-83. <https://doi.org/10.1111/1556-4029.12094>
29. Kroman A, Kress T, Porta D. Fracture propagation in the human cranium: a re-testing of popular theories. *Clinical Anatomy*. 2011 Apr;24(3):309-18. <https://doi.org/10.1002/ca.21129>
30. Geserick G, Krockner K, Wirth I. Puppe's rule--a literature review. *Archiv für Kriminologie*. 2012;229(1-2):34-43. PMID:22448468
31. Cattaneo C, Andreola S, Marinelli E, Poppa P, Porta D, Grandi M. The detection of microscopic markers of hemorrhaging and wound age on dry bone: a pilot study. *The American journal of forensic medicine and pathology*. 2010 Mar 1;31(1):22-6. doi: 10.1097/PAF.0b013e3181c15d74
32. De Boer HH, Van der Merwe AE, Hammer S, Steyn M, Maat GJ. Assessing post-traumatic time interval in human dry bone. *International Journal of Osteoarchaeology*. 2015 Jan;25(1):98-109. <https://doi.org/10.1002/oa.2267>
33. World Health Organization-Burns.[updated 2018 March 6 ;cited 2019 Jan 16] Available from: <https://www.who.int/news-room/fact-sheets/detail/burns>
34. Pekka S, Knight B. The pathology of burns. *Bernard knight's forensic pathology*, 3rd edn. Oxford University Press Inc., New York. 2004;322.
35. Bloemsma GC, Dokter J, Boxma H, Oen IM. Mortality and causes of death in a burn centre. *Burns*. 2008 Dec 1;34(8):1103-7. <https://doi.org/10.1016/j.burns.2008.02.010>
36. Kobayashi K, Ikeda H, Higuchi R, Nozaki M, Yamamoto Y, Urabe M, Shimazaki S, Sugamata A, Aikawa N, Ninomiya N, Sakurai H. Epidemiological and outcome characteristics of major burns in Tokyo. *Burns*. 2005 Jan 1;31(1):S3-11. <https://doi.org/10.1016/j.burns.2004.10.007>
37. Palmu R, Isometsä E, Suominen K, Vuola J, Leppävuori A, Lönnqvist J. Self-inflicted burns: an eight year retrospective study in Finland. *Burns*. 2004 Aug 1;30(5):443-7.

- <https://doi.org/10.1016/j.burns.2004.01.020>
38. Masud U, Saeed A, Nadeem S. Death from Burns: A Twenty Years Autopsy Study in Faisalabad, Pakistan.
 39. Saaiq M, Ashraf B. Epidemiology and outcome of self-inflicted burns at Pakistan Institute of Medical Sciences, Islamabad. World journal of plastic surgery. 2014 Jul;3(2):107. PMID: 25489533
 40. Othman N, Kendrick D. Epidemiology of burn injuries in the East Mediterranean Region: a systematic review. BMC public health. 2010 Dec;10(1):83. <https://doi.org/10.1186/1471-2458-10-83>
 41. Shrivastava PS, Shrivastava SR. An epidemiological study of adult female burns patients admitted in a tertiary care hospital. Progress in Health Sciences. 2012 Dec 1;2(2):21-9. <http://progress.umb.edu.pl/node/4>