

THE PATTERN OF MEDIAL CLAVICULAR EPIPHYSEAL OSSIFICATION: PRELIMINARY STUDY OF A SRI LANKAN POPULATION

Pranavan S.¹, Kalubowila K.C.², Senanayake G.³, Liyanage U.A.² & Gunawardena S.A.²

¹*Institute of Forensic Medicine and Toxicology, Sri Lanka*

²*Faculty of Medicine University of Colombo, Sri Lanka*

³*Faculty of Medicine Sir John Kotelawala Defence University.*

Corresponding author: Pranavan S.

E-mail: selliahpranavan@yahoo.com

 <https://orcid.org/0000-0002-0852-658X>

ABSTRACT

Forensic Age Estimation (FAE) in living is required in many civil and criminal circumstances where documentary proof of age is unavailable. In Sri Lanka, 16-21 age range has many statutory age limits. Though international guidelines recommend CT scanning of medial clavicular epiphyses for forensic age estimations within this age range, Sri Lanka does not have any population-specific reference standards for this modality.

The objective of this study was to describe the pattern of medial clavicular epiphyseal fusion among Sri Lankans aged 15-30 years.

Chest, neck and pulmonary angiography CT scans of patients between 15-30 years performed in two tertiary hospitals were reported independently by two radiologists using the five-stage classification for medial clavicular ossification by Schmeling et al. (2004). Interobserver reliability was assessed using Cohen's Kappa coefficient. A preliminary descriptive analysis of the first 46 cases was done using SPSS.

There were 25 males and 21 females. Majority (80%) were 18 years and above. The oldest with stage 1 was 16 years. The youngest for stages 2 and 3 were both 17 years. Stages 4 and 5 were seen in 67% of cases and none were below 20 years. This trend was similar to previously published studies.

From the preliminary results, it appears that only stages 4 and 5 can be used reliably to determine if a person is >18 years. Stages 2 and 3 are likely to indicate that the person is >16 years. Clavicular epiphyseal fusion shows good potential to be a reliable FAE method in Sri Lanka.

Keywords: *Forensic age estimation; population-specific reference databases; skeletal maturation; legal age limits*



All articles in Sri Lanka Journal of Forensic Medicine, Science & Law are licensed under the terms of the Creative Commons Attribution-Non Commercial 4.0 International License.

INTRODUCTION

Estimation of the age in living adolescents and young adults has significant importance both in civil and criminal legal matters. In many western countries, the emphasis on Forensic Age Estimation has mainly been on illegal immigrants seeking refugee status without proper birth records^{1,2}. In a variety of criminal and civil proceedings, different age limits have forensic importance. In Sri Lanka, the age range 16 to 21 years include many statutory age limitations such as the age of consent for sexual intercourse (16 years), age of marriage (18 years), fitness for driving (18 years) and the sale of intoxicants (21 years)³. Often it is to determine whether an individual is an adult or a minor and the commonly used age limit for adulthood in most jurisdictions is 18 years.

The medical assessment of a person's age is based primarily on determining the maturity of the dentition and skeletal system⁴. A person's growth and development, cognitive and intellectual maturity as well as development of secondary sexual characteristics can also be used but have a lesser reliability on their own. The updated recommendations of Study Group on Forensic Age Diagnostics for age estimations in living individuals in criminal proceedings by the German Group for Forensic Age Diagnostics published on 2008⁵, recommends that a physical examination, x-ray examination of the left hand, dental status and x-ray of dentition be performed in each case. It further recommends a radiological evaluation of clavicle, if the skeletal maturation of hand is completed⁵.

The lack of population specific reference standards on skeletal maturation has been a controversial issue in forensic age

estimations. Available studies on major populations have shown that skeletal maturation takes place in identical, defined stages. However, the rate of ossification could be affected by numerous factors including socioeconomic status, environment, and ethnicity^{6,7}. Though ethnicity was mentioned as one of the factors, the studies mainly concentrated on the populations of different regions. Therefore, application of European reference standards on an individual from a lower socio-economic background would lead to underestimation of that person's age⁸. Therefore, it is recommended that repositories of population-specific databases from lower socio-economic countries are established and used as reference material for forensic age estimation when individuals from that ethnicity or region are being investigated⁹.

The imaging methods used to assess the maturity of hand and wrist found to be one of the reliable methods for age estimation in children up to 14 to 15 years¹⁰. The Study Group on Forensic Age Diagnostics recommends evaluation of medial epiphyses of the clavicles by thin-section computed tomography (CT) in adolescents and young adults because sexual maturation, hand bone ossification, and third molar tooth growth has already been completed during the adolescent period.¹¹ Recent studies have shown that this method has a higher level of reliability in forensic age estimations in adolescents and young adults within the age ranges of 16-21 years¹²⁻¹⁴.

However, the fusion pattern of medial clavicular epiphysis has not been explored previously in a Sri Lankan population. Therefore, this study is aimed to develop population-specific reference standards for 15 to 30-year-old Sri Lankans. This paper

presents a preliminary analysis of the data obtained during the first year of the study to evaluate the feasibility of expanding into a larger nationwide reference database.

MATERIALS AND METHODS

A retrospective analysis was done of all retrievable CT scans of patients between 15 to 30 years who have undergone chest CT, CT pulmonary angiography and CT neck performed at the Department of Radiology at National Hospital Sri Lanka (NHSL), and Colombo South Teaching Hospital (CSTH) over a one-year period commencing from August 2018. The chronological age was confirmed by hospital records. Exclusion criteria included scans with improper chronological age records, diagnosis of any significant bone disease such as osteogenesis imperfecta, endocrinological disorders, chronic illness or long-term medications that may affect the bone development, presence of artefacts or significant anatomic variations, fractures of the clavicle or sternum and CT evidence of bone dysplasia.

High-resolution thin-slice CT images were used for analysis. The stages of clavicular maturation were reported by two radiologists experienced in age estimation, blinded to the chronological age and to each other. Images were reported on Vitrea 2 work advanced visualization workstation.

The five-stage classification system by Schmeling et al. 2004 was used in the current study to evaluate the clavicular ossification¹².

- Stage 1: non-ossified epiphysis
- Stage 2: isolated ossified epiphysis
- Stage 3: partial bony fusion between epiphysis and metaphysis
- Stage 4: complete bony fusion between epiphysis and metaphysis with definable epiphyseal scar
- Stage 5: complete bony fusion between epiphysis and metaphysis without visible epiphyseal scar

Data analysis were carried out using Statistical Package for the Social Sciences (SPSS) version 23. The age distribution and inter-observer agreement on the ossification grade were assessed. The ossification grade at each age was expressed as a minimum, maximum mean and median range. The age-ossification relationship was visually evaluated using a box-whisker plot analysis.

The Inter-observer agreement between the radiologists with regard to the ossification grade of medial clavicular epiphysis was calculated using kappa statistics in 31 cases. The following criteria were used to interpret the agreement: kappa value of less than 0.20 indicated poor agreement; a kappa value of 0.21–0.40, fair agreement; a kappa value of 0.41–0.60, moderate agreement; a kappa value of 0.61–0.80, substantial agreement; and a kappa value of more than 0.81, excellent agreement¹⁵.

The ethics clearance was obtained from the ethics committees of all selected hospitals.

RESULTS

There were 46 patients included in the study.

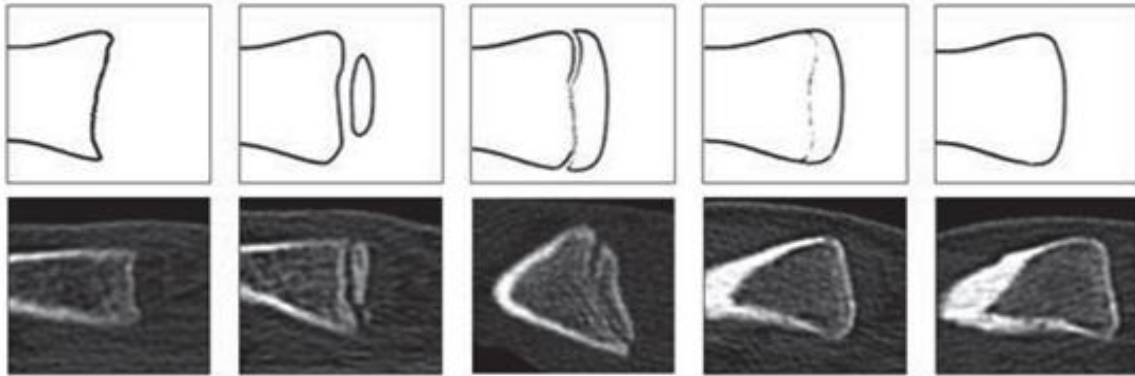


Figure 1: The stages of maturity status of edial clavicular ossification⁹

❖ **Figure 2** - Cases by age and sex.

Male				Female				
5	5	5		1				Key: 6 2 7 means 26-year-old male 27-year-old female
7	7	6		1	6	7	7	
9	9	8		1	8			
1	1	0		2	0	1		
	3	2		2	2	3		
				2	4	4	5 5 5	
7	6	6		2	7	7	7	
9	9	8		2	8	9	9	
0	0	0		3	0	0		

Figure 2: Stem-leaf plot of cases by age and gender (n=46)

Twenty-five (54.3%) were female and 21 (45.7%) male. There were 9 patients below the age of 18 years.

❖ **Figure 3** - Distribution of ages within each clavicular maturation stage.

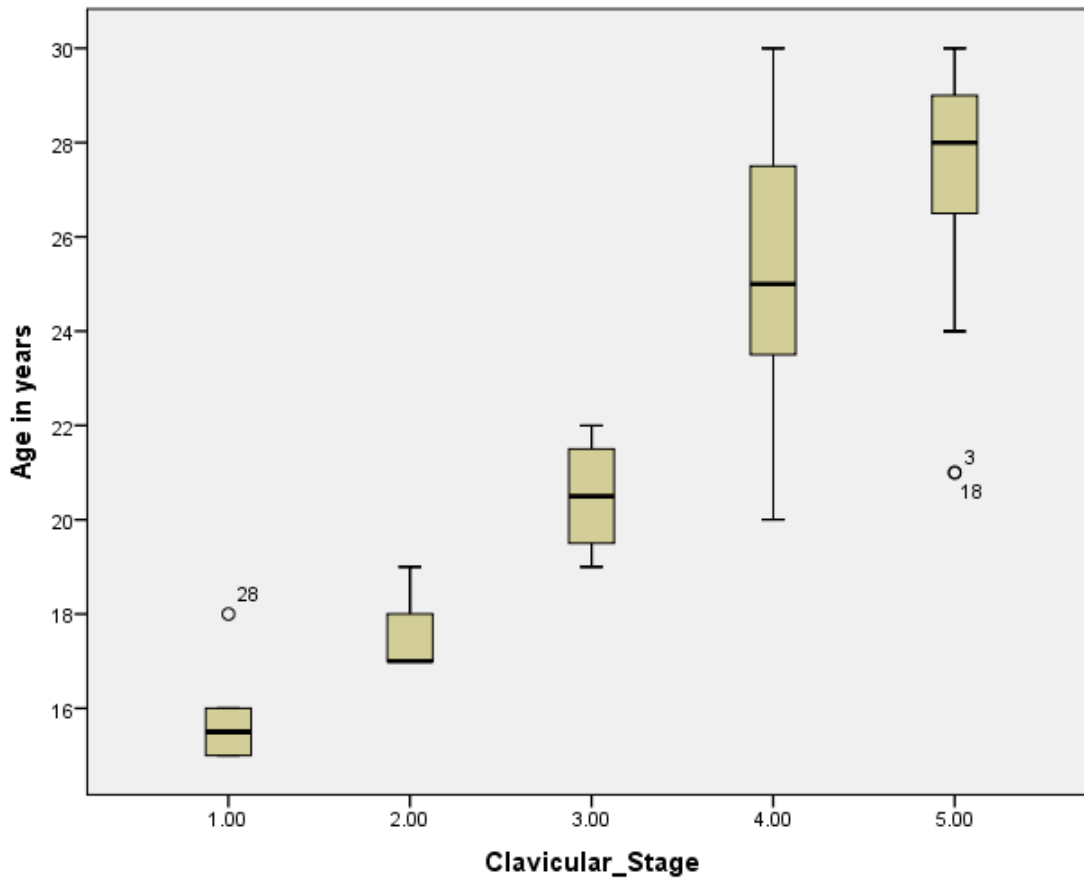


Figure 3: Scatter plot graph showing the relationship between age and averaged ossification grades.

One outlier data was noted at the age of 18 on stage 1, and two outlier data was noted on at the age of 21 on stage 5. Those data were excluded from further analysis.

Table 1 shows the descriptive statistics of the clavicular stages with the maximum, minimal age limits mean and median values of each ossification stages after removing the outlier data on tested samples.

Table 01: Statistical parameters by gender for ossification stages 1–5 after removing the outlier data.

Stage	No.	Min.-Max.	Mean	Median
1	5	15.0-16.0	15.4	15
2	6	17.0-19.0	17.5	17
3	4	19.0-22.0	20.5	20.5
4	15	20.0-30.0	25.81	25.5
5	13	24.0-30.0	27.83	28

Stage 1 was seen in five patients between 15 and 16 years. There were 6 patients in Stage 2, where the minimum age of appearance was 17 years, and was not seen beyond 19 years. Stage 3 was seen in 4 patients between 19 to 22 years. Stage 4 was seen in 15 patients where the youngest was 20 years. Stage 5 was seen in 13 patients and the minimum age of appearance was 21 years.

When comparing the trends of maturation of our study population with other published studies, we found that earliest appearance of stage 3 is 16 years, whereas it is 19 years in our study.

There were 31 cases which were reviewed by both radiologists (Table 2). Discrepancies were seen in 7 cases one involving stages 2 and 3 and six involving stages 4 and 5. The Cohen Kappa score for inter-observer agreement was 0.626.

Table 2: Interobserver variation between the two radiologists

(The numbers in bold indicate cases where there were discrepancies)

	Clavicular stage	Radiologist_B					Total
		1	2	3	4	5	
Radiologist_A	1	3					3
	2		4	1			5
	3			2			2
	4				6	3	9
	5				3	9	12
Total		3	4	3	9	12	31

Table 03: Review of some CT studies on different population with medial clavicular ossification stages

Study	Number of samples	Study population	Age (years)		
			Stage 3	Stage 4	Stage 5
Schulz et al. ¹⁶	629	Germany	16-28	21-30	21-30
Schulze et al. ¹⁹	100	Germany	16-25	19-25	-
Franklin et al. ²⁰	388	Australia	17-24	20-36	24-35
Pattamapaspong et al. ²¹	409	Thailand	15-27	18-29	20-29
Zhang et al. ²²	752	China	16-26	19-26	-
Ufuk et al. ¹⁸	300	Turkey	16-26	18-26	21-30
Kreitner et al. ¹⁷	279	Germany	16-26	22-29	-
Present study	46	Sri Lankan	19-21	20+	24+

DISCUSSION

This study presents a preliminary finding of an ongoing research intended to develop a population specific reference standard for the use of medial clavicular epiphyseal fusion staging for forensic age estimation in the living. We evaluated the ossification of the medial clavicular epiphysis in chest CT scans of Sri Lankans between the ages of 15 and 30 years. The averaged ossification grades had a positive correlation with increasing age which were consistent with those of previous studies¹⁶⁻²².

In our preliminary analysis of 46 individuals, stage 1 was seen between 15-16 years except for one outlier who was 18 years. The earliest appearance of stage 2 was 17 years and stage 3 was 19 years. The youngest with stage 4 was aged 20 years and except for two outliers who were 21 years old, the minimum age of stage 5 was found to be 24 years. Both stages 4 and 5 were seen at 30 years indicating that though complete fusion of the medial epiphysis occurs the presence of the scar could persist even beyond 30 years in our population. Table 3 compares our results with several studies conducted in different populations. The closest comparable trend is from an Australian population study²⁰. A notable difference was that the earliest appearance of stage 3 was seen in much older individuals than in other studies and was not seen beyond 21 years. Based on the criteria used to interpret the kappa score value²³, substantial agreement was achieved between the two radiologists in assessing the clavicular stages.

According to Sri Lankan law, the minimum age of consent for sex is 16²⁴. Studies on German, Chinese and Turkish populations^{16-19,22} showed that stage 3 first appears at the age of 16. However, in Thailand population, it appears at the age of

15, and in Australian populations, it appears at the age of 17^{20,21}. In this study, only stage 1 was seen in those less than 16 years old. With larger numbers it may be possible to use stages 1 and 2 to clearly distinguish the probability of being above or below 16 years. Stage 3 however, appeared much later in our study and has the potential to be a reliable indicator of a person being above 16 years. This would be a very useful tool when age is disputed in alleged sexual abuse cases in the adolescent period.

Except for the two outliers (who were also 21 years), the minimum age of stage 5 could be considered as 24 years which could be considered as a safe indicator of a person being above 21 years. Age 21 is the legal age limit for selling and consuming of intoxicants in Sri Lanka. Since conventional dental and hand radiographic methods have no value over the age of 18, this could be safely used to estimate the age of 21 in legal cases.

The test for inter-observer error showed substantial agreement between the two radiologists which suggests that this method of age estimation is highly reproducible.

Many previous studies based on CT scan were not divided by sex. Sex was compared in two studies and showed a significant difference in sex^{16,25}. In both studies, the difference was noted in stage 2, and females found to reach the stage earlier than males. However, the study conducted on the Turkish population did not find any significant difference between male and females on ossification stages¹⁸. Due to the small sample size, we did not attempt comparison between the sexes during this preliminary analysis.

LIMITATIONS

The generalizability of these findings is limited due to the small sample size. With a large sample size, the trends noted here could change significantly. Although we identified and excluded the outlier data in the further analysis, given the small sample size there is a possibility that they may even be normal occurrences in the population.

We did not have the necessary resources to consider the socio-economic status of the individual patients through this study which may influence the results. There are significant differences in socio-economic standards within Sri Lanka²⁶ and differences in nutritional status have been reported even within a single urban locality²⁷. This factor would be taken into consideration when developing the larger database for the country.

As this was a retrospective study the chronological age of the participants was obtained only from hospital records. However, it was verified by contacting them over the phone. No discrepancy was noted in the obtained ages.

CONCLUSION

The preliminary results of our study revealed that there is good potential for the medial clavicular epiphysis ossification stages to be reliably used to diagnose important legal age limits in Sri Lanka. Stage 3 is likely to be a reliable indicator that an individual has reached the age of 16 years. Stages 4 and 5 could be used to indicate an age above 18 years with stage 5 being highly suggestive of being older than 21 years.

RECOMMENDATIONS

There appear to be notable differences in the trends of clavicular epiphyseal ossification when compared with published studies in other populations and therefore it would be extremely important to develop and use a reference database specific to Sri Lanka.

ACKNOWLEDGEMENT

I would like to thank Dr. KWM Senarath and Dr. WAN Gunawardhana for their contribution in data collection.

REFERENCE

1. Schmeling A, Olze A, Reisinger W, Geserick G. Age estimation of living people undergoing criminal proceedings. *The Lancet*. 2001 Jul; 358(9276):89-90.
2. Dünkel F, Van Kalmthout A, Schüler-Springorum H, editors. *Entwicklungstendenzen und Reformstrategien im Jugendstrafrecht im europäischen Vergleich*. Forum Verlag Godesberg.
3. Penal Code Amendment act No 22 of 1995 Parliament of The Democratic Socialist Republic of Sri Lanka.
4. Schmeling A, Reisinger W, Geserick G, Olze A. Age estimation of unaccompanied minors: Part I. General considerations. *Forensic science international*. 2006 May; 159:S61-4.
5. Schmeling A, Grundmann C, Fuhrmann A, Kaatsch HJ, Knell B, Ramsthaler F, Reisinger W, Riepert T, Ritz-Timme S, Rösing FW, Rötzscher K. Criteria for age estimation in living individuals. *International journal of legal medicine*. 2008 Nov; 122(6):457.
6. Garn SM, Sandusky ST, Rosen NN, Trowbridge F. Economic impact on postnatal ossification. *American journal of physical anthropology*. 1973 Jan; 38(1):1-3.

7. Cardoso HF. Environmental effects on skeletal versus dental development: using a documented subadult skeletal sample to test a basic assumption in human osteological research. *American journal of physical anthropology*. 2007 Feb; 132(2):223-33.
8. Schmeling A, Reisinger W, Loreck D, Vendura K, Markus W, Geserick G. Effects of ethnicity on skeletal maturation: consequences for forensic age estimations. *International journal of legal medicine*. 2000 Aug; 113(5):253-8.
9. Gunawardena SA, Liyanage UA, Weeratna JB, Mendis ND, Perera HJ, Jayasekara RW, et al. Forensic age estimation in anti-piracy trials in Seychelles: Experiences and challenges faced. *Forensic science international*. 2017 Jan; 270:278-e1.
10. Schmidt S, Nitz I, Ribbecke S, Schulz R, Pfeiffer H, Schmeling A. Skeletal age determination of the hand: a comparison of methods. *International journal of legal medicine*. 2013 May; 127(3):691-8.
11. Schmeling A, Olze A, Reisinger W, Geserick G. Age estimation of living people undergoing criminal proceedings. *The Lancet*. 2001 Jul; 358(9276):89-90.
12. Schmeling A, Schulz R, Reisinger W, Mühler M, Wernecke KD, Geserick G. Studies on the time frame for ossification of the medial clavicular epiphyseal cartilage in conventional radiography. *International journal of legal medicine*. 2004 Feb; 118(1):5-8.
13. Kumar R, Madewell JE, Swischuk LE, Lindell MM, David R. The clavicle: normal and abnormal. *Radiographics*. 1989 Jul; 9(4):677-706.
14. Webb PA, Suchey JM. Epiphyseal union of the anterior iliac crest and medial clavicle in a modern multiracial sample of American males and females. *American Journal of Physical Anthropology*. 1985 Dec; 68(4):457-66.
15. Landis JR, Koch GG. The measurement of observer agreement for categorical data. *Biometrics*. 1977 Mar:159-74.
16. Schulz R, Mühler M, Mutze S, Schmidt S, Reisinger W, Schmeling A. Studies on the time frame for ossification of the medial epiphysis of the clavicle as revealed by CT scans. *International journal of legal medicine*. 2005 May; 119(3):142-5.
17. Kreitner KF, Schweden F, Schild HH, Riepert T, Nafe B. Computerized tomography of the epiphyseal union of the medial clavicle: an auxiliary method of age determination during adolescence and the 3d decade of life?. *RoFo: Fortschritte auf dem Gebiete der Rontgenstrahlen und der Nuklearmedizin*. 1997 Jun; 166(6):481-6.
18. Ufuk F, Agladioglu K, Karabulut N. CT evaluation of medial clavicular epiphysis as a method of bone age determination in adolescents and young adults. *Diagnostic and Interventional Radiology*. 2016 May; 22(3):241.
19. Schulze D, Rother U, Fuhrmann A, Richel S, Faulmann G, Heiland M. Correlation of age and ossification of the medial clavicular epiphysis using computed tomography. *Forensic science international*. 2006 May; 158(2-3):184-9.
20. Franklin D, Flavel A. CT evaluation of timing for ossification of the medial clavicular epiphysis in a contemporary Western Australian population. *International journal of legal medicine*. 2015 May; 129(3):583-94.
21. Pattamapaspong N, Madla C, Mekjaidee K, Namwongprom S. Age estimation of a Thai population based on maturation of the medial clavicular epiphysis using computed tomography. *Forensic science international*. 2015 Jan; 246:123-e1.
22. Zhang K, Chen XG, Zhao H, Dong XA, Deng ZH. Forensic Age Estimation Using Thin-Slice Multidetector CT of the Clavicular Epiphyses among Adolescent Western Chinese. *Journal of forensic sciences*. 2015 May; 60(3):675-8.

23. Kreitner KF, Schweden FJ, Riepert T, Nafe B, Thelen M. Bone age determination based on the study of the medial extremity of the clavicle. *European radiology*. 1998 Sep; 8(7):1116-22.
24. Flecker H. Roentgenographic observations of the times of appearance of epiphyses and their fusion with the diaphyses. *Journal of anatomy*. 1932 Oct; 67(Pt 1):118.
25. Kellinghaus M, Schulz R, Vieth V, Schmidt S, Schmeling A. Forensic age estimation in living subjects based on the ossification status of the medial clavicular epiphysis as revealed by thin-slice multidetector computed tomography. *International journal of legal medicine*. 2010 Mar; 124(2):149-54.
26. Pathmeswaran A, Jayatissa R, Samarasinghe S, Fernando A, De Silva RP, Thattil RO, et al. Health status of primary schoolchildren in Sri Lanka. *Ceylon Medical Journal*. 2010 Feb; 50(2).
27. Wickramasinghe VP, Lamabadusuriya SP, Atapattu N, Sathyadas G, Kuruparanantha S, Karunarathne P. Nutritional status of schoolchildren in an urban area of Sri Lanka. *Ceylon Medical Journal*. 2010 May; 49(4)