

A MATERNAL DEATH DUE TO AN ILLEGAL ABORTION

- A Case Report -

W.N.S. Perera & P. Paranitharan

Department of Forensic Medicine, Faculty of Medicine, Ragama.

Introduction

Pregnancy places a woman at some risk for illness and death. This risk may be gladly assumed with a desired pregnancy. Unwanted pregnancy places a woman at additional risk if she seeks abortion as safe services are not often available.^{1,2} This risk may be varying from morbidity such as infertility to mortality.

The World Health Organization estimates that 25 to 50 percent of the 500,000 maternal deaths that occur every year result from illegal abortion.³ Most of these deaths occur in underdeveloped countries. The data on preventable morbidity and mortality from septic abortion are staggering and well documented.^{4, 11}

Case history

A 39 year old lady living together with her male partner had missed periods and pregnancy was confirmed. She went to a "place for abortion". At that place a tube was inserted into her vagina and suction was done by the "abortionist". After coming home she had severe vaginal bleeding and chills. Second day she was admitted to the hospital with fever, abdominal pain, heavy vaginal bleeding and low blood pressure. Third day evacuation of retained products of conception and laparotomy was performed suspecting bowel perforation. Subsequent to the surgery she had cardiac arrest and was ventilated. Further she had persistent hypotension elevated liver enzymes, deteriorating renal functions, coagulation defects and bleeding tendency. On fourth day she died in the Intensive Care Unit in spite of vigorous resuscitation.

Post mortem examination

At autopsy she was pale; there was haemorrhage into the venepuncture sites, confluent petechial haemorrhages on the body and no injuries to the genitalia. Surgical incision on the abdomen was intact and not infected. There was subarachnoid haemorrhage, lungs were heavily congested. Bowels were dusky, omentum was soft. Liver had nutmeg appearance, kidneys were reddish and swollen, spleen was soft. Uterus was enlarged, uterine tubes and ovaries showed haemorrhagic patches with bluish discoloration. There were foul smelling blood clots in the irregular uterine cavity. (*Figure:1*) Uterine wall was devoid of perforations.

Pseudomonas infection was positive from the retained products of conception. Histology revealed features of organ failure, necrotic material with remaining fetal tissue in the uterus (*Figure:2*) and neutrophil infiltration into the myometrium. (*Figure:3*) Cause of death was ascertained as complications of septic abortion.

Discussion

Mortality and morbidity from septic abortions are frequent in countries where the induced abortions are illegal or inaccessible. In Sri-Lanka induced abortion can be done legally only to save the life of the mother.

To cause the death of this lady, two major factors were contributed to the development of complications of septic abortion. Those are presence of retained products of conception following illegal abortion and infection introduced into the uterus at the time of abortion. Abortion-related deaths result primarily from sepsis.^{8,9} Infection

usually begins as endometritis and involves the endometrium and any retained products of conception. If not treated, the infection may spread further into the myometrium and parametrium. The patient may develop bacteremia and sepsis at any stage of septic abortion. In this case, presence of highly virulent pseudomonas infection in the uterus can act as a focus of infection releasing endotoxins and exotoxins. This will cause systemic inflammatory response as a reaction to bacterial infection. Further release of vasoactive substances is associated with organ dysfunction, hypoperfusion or hypotension, metabolic abnormalities, and microcirculatory failure leading to septic shock. In this case there were evidence of bleeding into tissues, subarachnoid haemorrhage due to coagulation and bleeding defects. Macroscopic and microscopic appearances of the organs as well as clinical investigations suggested organ dysfunctions and metabolic defects. Combined

complications of sepsis had caused the death of this person.

Primary prevention of septic abortion includes provision of effective and acceptable contraception; provision of safe, legal abortion services in the case of contraceptive failure; and appropriate medical management of abortion.¹¹

Conclusion

Serious complications are resulted from illegal abortion causing morbidity and mortality. Reducing maternal mortality by preventing illegal abortion is a challenge. Mostly ethical, religious and political obligations prevent discussion on health values to prevent maternal deaths from illegal abortions. Therefore we need to initiate a discussion among medical and legal community to reduce the number of maternal deaths from illegal abortions.

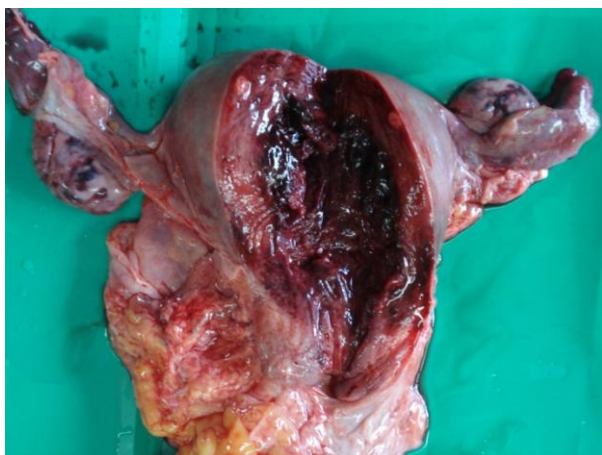

Figure 1: Blood clots in the uterus

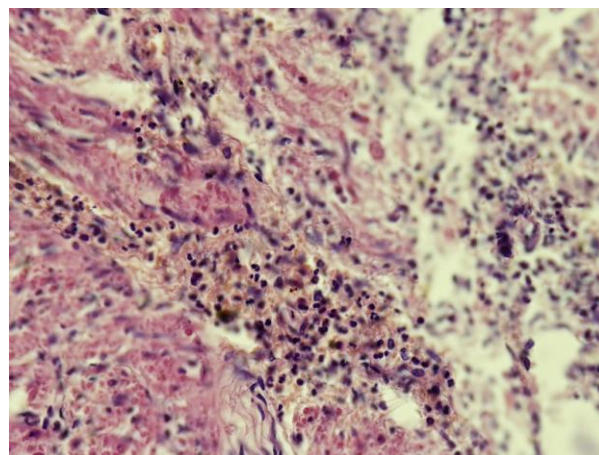


Figure 2: Neutrophils in the Myometrium

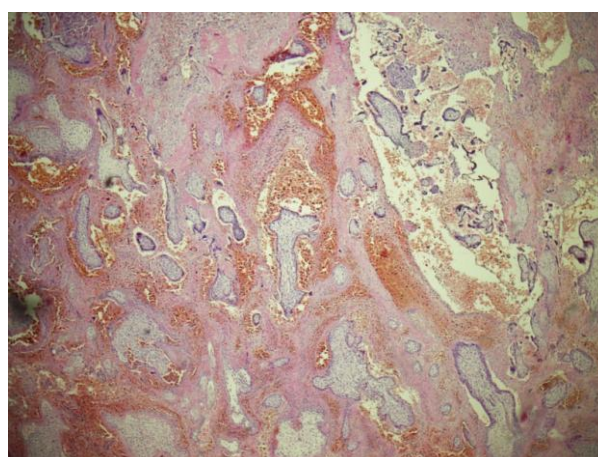


Figure 3: Chorionic villi in the uterus (Slide from ERPC)

Reference

1. Villarreal J. Commentary on unwanted pregnancy, induced abortion, and professional ethics: a concerned physician's point of view. *International Journal of Gynaecology & Obstetrics* 1989
2. Sai FT, Nassim J. The need for a reproductive health approach. *International Journal of Gynaecology & Obstetrics* 1989; 3: Suppl: 103-113.
3. Mahler H. The safe motherhood initiative: a call to action. *Lancet* 1987; 1:668-670.
4. Liskin LS. Complications of abortion in developing countries. *Population Report* [F] 1980; F(7):F105-F155.
5. Toure B, Thonneau P, Cantrelle P, Barry TM, Ngo-Khac T, Papiernik E. Level and causes of maternal mortality in Guinea (West Africa). *International Journal of Gynaecology & Obstetrics* 1992; 37:89-95.
6. Kampikaho A, Irwig IM. Incidence and causes of maternal mortality in five Kampala hospitals, 1980-1986. *East African Medical Journal* 1991; 68:624-631.
7. Okonofua FE, Onwudiegwu U, Odunsi OA. Illegal induced abortion: a study of 74 cases in Ile-Ife, Nigeria. *Tropical Doctor* 1992; 22:75-78.
8. Konje JC, Obisesan KA, Ladipo OA. Health and economic consequences of septic induced abortion. *International Journal of Gynaecology & Obstetrics* 1992; 37:193-197.
9. Fauveau V, Koenig MA, Chakraborty J, Chowdhury AI. Causes of maternal mortality in rural Bangladesh, 1976-85. *Bull World Health Organ* 1988; 66:643-651.
10. Laguardia KD, Rotholz MV, Belfort P. A 10-year review of maternal mortality in a municipal hospital in Rio de Janeiro: a cause for concern. *Obstetrics & Gynecology* 1990; 75:27-32.
11. Phillip G. Stubblefield and David A. Grimes. Septic abortion. *New England Journal of Medicine* 1994; 331:310-314.