

## POTENTIAL MEDICAL NEGLIGENCE - A CASE REPORT -

Vidanapathirana M & Beneragama DH<sup>2</sup>

<sup>1</sup>Department of Forensic Medicine, <sup>2</sup>Department of Pathology,  
Faculty of Medical Sciences, University of Sri Jayewardenepura

### Introduction

Though cases of medical negligence are not common causes of litigation in our country, such incidents surface at autopsy investigations every now and then. Since the relatives are more focused on disposal of the body and religious activities following a death, such incidents of possible negligence seem to be ignored.

### Case report

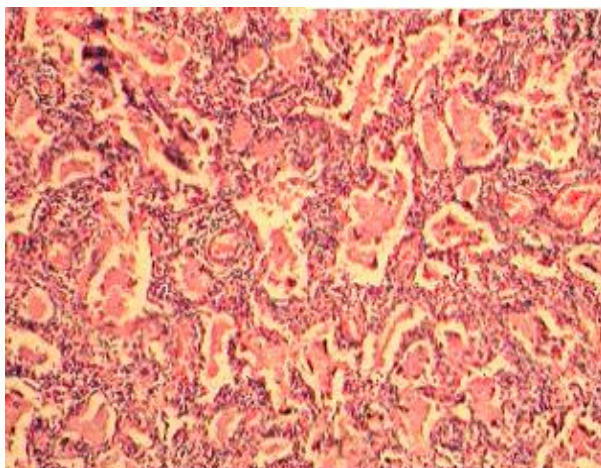
A four month old baby boy, weighing 4,400g, from a consanguineous marriage was admitted to a tertiary care hospital with fever and dyspnoea. He has had diffuse ichthyosis since one month of age. The problems identified by the clinicians were recurrent chest infection, failure to thrive and immunodeficiency. The child had been immunized with DPT and oral polio vaccines at the age of 2 months.

The haematological investigations showed a neutrophil leucocytosis compatible with a bacterial infection. The child was discharged

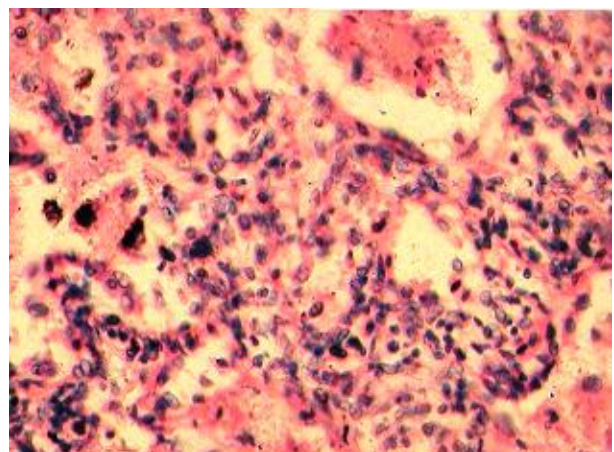
after 1 week with a diagnosis card stating that he had been 'Investigated for immunodeficiency and ichthyosis. On the same evening, the condition of the child worsened and was re-admitted to another tertiary hospital with severe shortness of breath, cyanosis and gasping. In spite of ventilation child died few hours after admission.

At autopsy, external examination showed ichthyosis, cyanosis and purpuric patches.

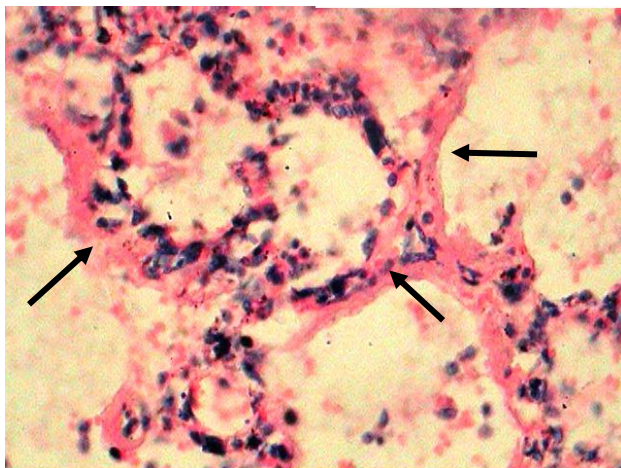
Internal examination revealed lungs weighing 100g each with bilateral patchy consolidation. The heart, brain and liver were unremarkable. Toxicology was negative. Histopathology of lungs revealed diffuse interstitial inflammation with chronic inflammatory cells composed of lymphocytes, plasma cells, macrophages, and scattered neutrophils. (*Figures 1,2*). There was diffuse alveolar damage with fluid within the alveoli. A hyaline membrane was noted lining some alveoli. (*Figure3*). These findings were compatible with an acute lung injury.



**Figure 1:** Diffuse interstitial inflammation and fluid-filled alveoli (H and E stain x 4)



**Figure 2:** Diffuse alveolar damage with loss of epithelium and interstitial inflammation (H and E stain x40)



**Figure 3:** Diffuse alveolar damage with loss of epithelium and a hyaline membrane (arrows) (H and E stain x40)

## Discussion

Ichthyosis is an inherited disorder characterized by excessive scaling of skin with distinct pattern<sup>1</sup>. Higher chance of such appearance is found in consanguineous marriages and in immunodeficiency states<sup>1</sup>. These patients are more prone to recurrent chest infections which can result in further immunosuppression due to defects in T-cells, B-cells, and granulocytes and complement leading to secondary bacterial infection<sup>2</sup>. These patients show failure to thrive with a reduction of the expected weight gain<sup>3</sup>.

At autopsy, both lungs were congested with patchy areas of consolidation. Histopathology showed the presence of diffuse alveolar damage (DAD) with interstitial inflammation, vascular congestion and formation of hyaline membranes. The differential diagnoses considered for the acute lung injury (ALI) and DAD were dengue shock syndrome, interstitial pneumonia complicated by septicaemia following possible immunosuppression and a vaccine-induced lung injury. Features favouring dengue shock syndrome were presence of fever, purpuric rash and fluid within the alveoli. However, peripheral leucocytosis and the absence of hepatomegaly or a pleural effusion were more in favour of sepsis induced lung injury.

DAD is a descriptive term for the pathological findings following ALI of several causes which include infectious agents, inhalants, connective tissue disease, drugs, shock, sepsis and radiation<sup>5</sup>. The initial, exudative phase of DAD occurs in the first 6 days characterized by pulmonary oedema, hyaline membrane formation, alveolar wall oedema and microatelectasis. The second, reparative phase, which occurs later, is

characterized by hyperplasia of epithelial type II cells, interstitial mononuclear inflammatory infiltration and organizing alveolar exudates<sup>6</sup>.

Finally, the cause of death was given as diffuse alveolar damage caused by interstitial pneumonia probably of viral origin. Both respiratory syncytial and herpes simplex viral pneumonias are associated with giant cells on histopathological examination which was not present in this case. Coxsackie and enterovirus pneumonias are associated with myocarditis. Pneumonias due to echovirus can have hepatic and renal necrosis in infants<sup>7</sup>.

Negligence can be defined as doing something which a prudent and reasonable man would not do or omission to do something which a prudent and reasonable man would do in a given situation<sup>8</sup>. Medical negligence is the breach of a duty of care towards a patient which results in by an act of commission or omission, damage to a patient<sup>8</sup>.

In this case, the condition of the child on discharge was not documented by the clinicians and whether the child was safe to be discharged at the time is not known. The medical records show that the child was investigated for ichthyosis and immunosuppression but whether the child was diagnosed and treated for a potentially serious respiratory infection is in doubt. According to the mother, the child had been dyspnoeic at the time of discharge. This case exemplifies potential medical negligence as the child had been discharged in spite having diffusely damaged lungs and pulmonary oedema. This death may have been prevented if a proper medical examination had been done before being discharged.

## Conclusion

The case is an example of potential medical negligence and it highlights the importance of documentation of history and clinical examination on admission, daily assessment of vital parameters especially in a child who cannot express discomfort, or dyspnoea, and proper examination and assessment of patients to confirm that they have returned to safe levels before being discharged. The inquirer in to sudden deaths was made aware regarding the potential negligence.

## References

1. Ghai OP. Essential paediatrics. 2<sup>nd</sup> ed. New Delhi: Mehta offset works; 1990. 363
2. Cotran RS, Kumar V, Robbins SL. Robbins Pathologic basis of disease. 5<sup>th</sup> edition, Philadelphia: WB Saunders Company; 1994. 84-85
3. Gupte S. The short text book of paediatrics, 6<sup>th</sup> ed. New Delhi: align graphics; 1989. 37
4. National guidelines on management of dengue fever and dengue haemorrhagic fever in children and adolescents. Ministry of Health, Sri Lanka, December 2010.
5. Katzenstein AA, Askin FB. Surgical Pathology of Non-Neoplastic Lung Disease. Philadelphia, W.B.Saunders Company, 1990: 135.
6. Olson J, Colby TV, Elliott CG. Hamman-Rich syndrome revisited. Mayo Clin Proc 1990; 65: 1538-48.
7. Mason JK. Paediatric Forensic Medicine and Pathology. London: Chapman and Hall Medical; 1989. 169-171
8. Fernando R, De Silva LC. Basic principles of medical negligence, Colombo: the institute of health studies;1996, 1.