

REPEATED EPISODES OF PHYSICAL CHILD ABUSE: IS THE EXISTING SYSTEM ON MANAGING CHILD ABUSE DEFECTIVE IN SRI LANKA?

D.M.G. Fernando, D.H. Edussuriya & K.M.P.L. Dayaratne

Department of Forensic Medicine, Faculty of Medicine, University of Peradeniya

INTRODUCTION

According to Bernard Knight the child abuse syndrome exists when an infant or child suffers repetitive physical injuries inflicted by a parent or guardian, in circumstances that exclude accident.¹ Physical abuse represents approximately 70% of child abuse cases and may range from minor bruises to fatal haematomas.²

We report a case where the child has been repeatedly released into the same hazardous environment, in spite of a diagnosis of physical child abuse being made by pediatricians and judicial medical officers. The child has been subjected to repeated abuse resulting in multiple hospital admissions with 7 long bone fractures, multiple rib fractures and other life threatening injuries in her short life span of 20 months.

Case report

A five month old baby girl was brought to the General Hospital Nuwara-Eliya by her parents, who were estate laborers, with swelling of the left arm and excessive crying. There was no history of fever, trauma or fall. On examination the child was a febrile and the left arm was swollen and deformed. X-ray revealed a recent fracture of the mid shaft of left humerus (*Figure:1*) and healing fractures of mid shaft of ulna and radius of the same side (*Figure:2*). The baby was transferred to the Teaching Hospital Kandy for specialized orthopaedic management. The Judicial Medical Officer (JMO) referred the baby to the Eye surgeon, Neuro surgeon and Radiologist. Subsequently a diagnosis of non accidental injury was made and the Police and the Department of Probation and Child Care were informed.

However, the baby was discharged and sent back home.

Six months later, at the age of 11 months the same child was transferred to the Teaching Hospital Peradeniya with swelling of left lower limb and reduced movements. There was no history of trauma. X-ray revealed a recent spiral fracture in mid shaft of left femur (*Figure:3*).

Figure: 1

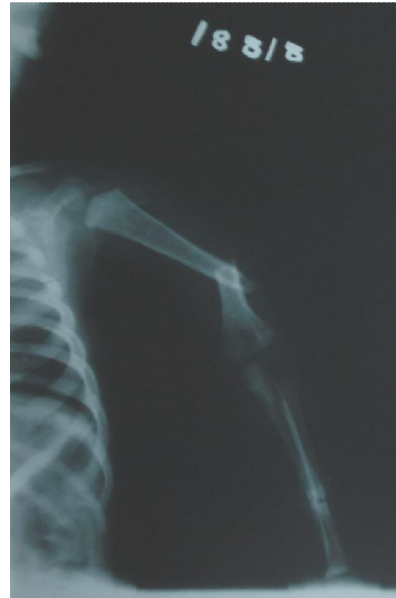
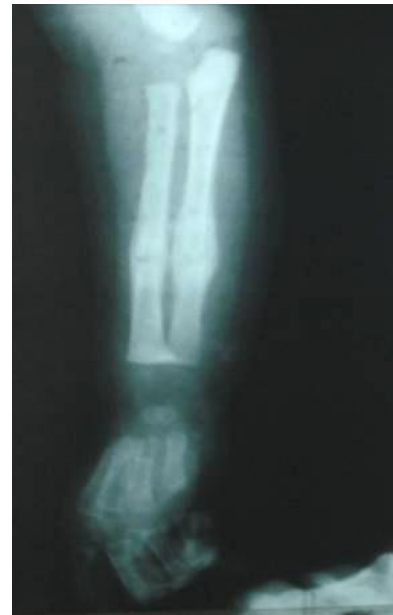
Figure: 2



The JMO was informed and a skeletal survey revealed multiple healing rib fractures and a transverse fracture with callus in the mid shaft of right ulna (*Figure:4*). A diagnosis of physical child abuse was made for the second time and the Police was informed, but the child was discharged, once again, without further action.

Figure: 3

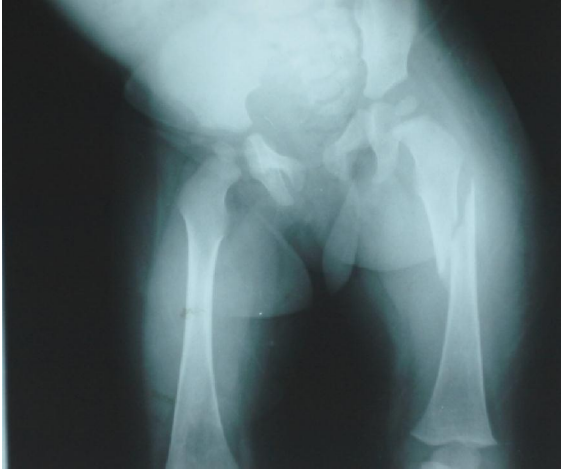


Figure: 5

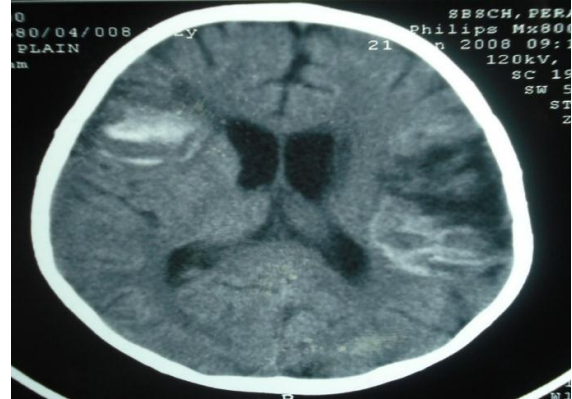


Figure : 4

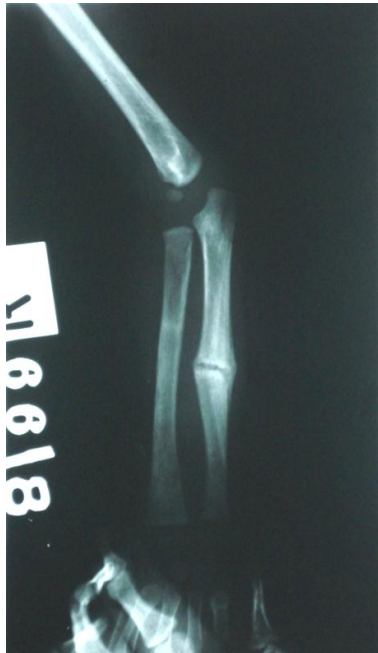
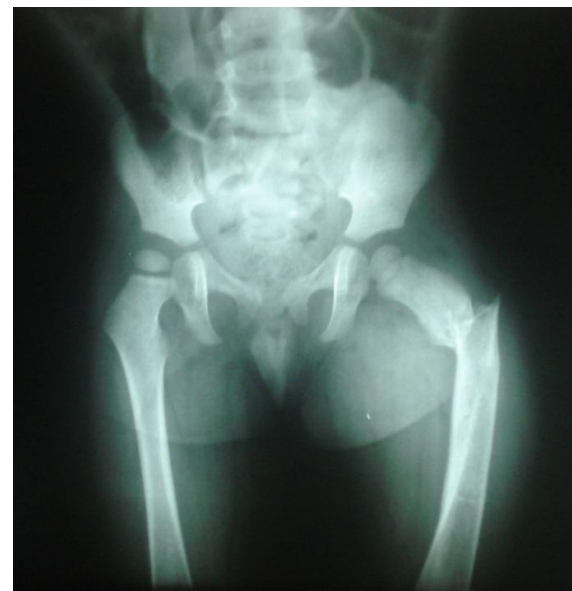
Figure : 6



Nine months later, at the age of 20 months, the child was again transferred to Teaching Hospital Peradeniya with focal fits and swelling of the left thigh. On examination, she was found to be drowsy and had a spastic right upper limb. CT scan of the brain revealed multiple haemorrhagic infarcts (*Figure:5*). The child was referred to the Department of Forensic Medicine and a skeletal survey revealed a recent fracture of the upper third of left femur (*Figure:6*) and evidence of previous fractures noted above in different stages of healing.³ In addition, a healed right tibial metaphyseal fracture was detected. Spine and skull X-rays were unremarkable. The baby was referred to the Eye Surgeon, Neurosurgeon, Cardiologist, Psychiatrist and Radiologist. Extensive investigations, including DEXA scan, was done to exclude pathological conditions.⁴

The mother and sibling were investigated to exclude hereditary bone diseases. A diagnosis of physical child abuse was made and the Police was informed.

The mother denied any form of abuse at home, but said that she keeps the baby in an estate crèche during day time since she was working. This estate day care center was usually managed by two attendants who looked after forty children.

A case conference was organized by the Department of Forensic Medicine, University of Peradeniya. This was facilitated by the Society against Child Abuse and Neglect (SCAN) which is a society consisting of representatives from Departments of Probation and Child Care, Social services, Labour, Education, police etc.. Members of SCAN, both parents of the child, the investigating Police officer, Estate Medical Assistant, both crèche attendants, Consultants in Paediatrics, Forensic Medicine, Radiology and

Community Medicine, Senior Registrar in Paediatrics and the academic staff of the Department of Forensic Medicine participated at the case conference. The crèche attendants stated that the child sustained no injuries whilst under their care. The Estate Medical Assistant stated that there had not been reports of similar cases in the estate since he commenced working there in January 2004, and the 4 year old sibling of this child did not have any notable injuries.

The participants, including the parents, unanimously agreed that the child should not be sent back to the same environment. The child was sent to a ðhomeö for safety.

The weight at the time of admission was way below the 3rd centile and the height was between the 3rd and the 10th centiles. The progress of the child was monitored and 1 ½ years later, the weight was above the 3rd centile and the height was between the 10th and 25th centiles showing an upward curve across the centile lines. Since admission, the child has not had any other fractures, significant injuries or further hospital admissions. However, both limbs on the right side were spastic with an increased tone and reflexes were exaggerated.

DISCUSSION

Recognition and management of child abuse by the physician demands a full measure of clinical acumen, skill and diplomacy. If not diagnosed, it may lead to continuous suffering of an innocent child, which might result in a permanent handicap or death. Mere diagnosis does not suffice, as illustrated in this case, but relevant authorities must take necessary action to prevent further harm being inflicted on the child. The reason for the repeated abuse suffered by this child, in spite of a correct diagnosis, has been the lack of coordination between doctors, police, and the department of probations and child care.

Even though many argue that institutionalization of an abused child results in further abuse of that child, the release of children into unsafe environments may lead to permanent physical or psychological damage to the child, or even death. Even if a correct diagnosis is made and the authorities are informed, it is important for us to look at each child individually in order to do what is in the best interest of that particular child. Therefore, development of lines of communication among those handling abused children is mandatory.

This case illustrates the lapses in our system for referral and follow up in cases of child abuse. The importance of linking services available for abused children is clearly seen.

RECOMMENDATIONS

The Departments of Forensic Medicine and Psychiatry, University of Peradeniya identified the need for linking of services related to children 5 years ago. Therefore, SCAN was created to facilitate the above. An already established organization of people working for the benefit of children is useful in situations relating to children, as links of communication are already established, and therefore a quicker and a more efficient service can be provided.

It is recommended that all Departments of Forensic Medicine and offices of Judicial Medical Officers form such links with the relevant departments associated with the care and protection of children, so that the children of today will grow up in a safer environment with prompt, efficient and quality care readily available for them for a better tomorrow.

ACKNOWLEDGEMENTS

We would like to acknowledge Dr. (Mrs) Badra Hevavithana, Consultant Radiologist, Faculty of Medicine, University of Peradeniya for reporting on X-rays & CT.

REFERENCES

1. Knight B, Saukko P. Knight's Forensic Pathology. 3rd edition.p.461-479.
2. Elkerdany A.A.F, Buhalqa A.A. Fatal physical child abuse in two children of a family. Annals of Saudi Medicine.1999;19(2):120-123.
3. Carty H.M.L. The radiological features of child abuse. Current Paediatrics. paediatrics.1995;5:230-235.
4. De Silva D.G. Child abuse: a manual for Medical Officers in Sri Lanka.2000