

DOI: <http://doi.org/10.4038/sljfmsl.v10i2.7829>


FATAL CASE OF WASP STINGING

Senanayake S.M.H.M.K. & Senarathna K.N.

Teaching Hospital, Anuradhapura, Sri Lanka

Corresponding Author: Senanayake S.M.H.M.K.

E-mail: dilruksena62@yahoo.co.uk

 <https://orcid.org/0000-0002-0441-5970>

Abstract

History - While a 2 year and 9 month old girl was going for a bath with the grandmother, they encountered a wasp net on the ground. The wasps stung the child. She developed anaphylaxis and died during transport from local hospital eight hours after the attack.

Postmortem examination- Thirty two skin lesions of 2-3 mm wide, circular, black macules were seen on back and limbs. Every black spot was surrounded by a 0.5 – 2cm size elevated red margin. Pink fluid in pleural cavities and peritoneal cavity, shock lungs and congested viscera were the only internal findings. Blood was hemolyzed and unsuitable for serum beta tryptase test. Based on the skin lesion, medical history and evidence of eye witness, the cause of death was pronounced as anaphylaxis following wasp attack.

Conclusion- Familiarization with skin lesions of wasp stings are important for Srilankan forensic medicine practitioners. Collection and preservation of ante mortem blood samples or early postmortem blood sample with serum separation by centrifuging is advisable in suspected anaphylaxis cases for future confirmatory investigation.

Key words: *Vespa affinis*, skin lesion, wasp sting, anaphylaxis, envenomation



All articles in Sri Lanka Journal of Forensic Medicine, Science & Law are licensed under the terms of the Creative Commons Attribution-Non Commercial 4.0 International License.

INTRODUCTION

In the animal kingdom, order Hymenoptera and suborder Apocrita includes bees, yellow jackets, hornets (wasps) and ants.¹ Wasps can be divided into social wasps and solitary wasps. Social wasps are aggressive and live as colonies in nests found in tree stumps, on rocks surfaces, tall structures like buildings, roof of caves, and mammal burrows. More than 25000 species of wasps exist in the world and cause more morbidity and mortality than other venomous animals.² In Sri Lanka, *Vespa affinis* (debara) species is mainly responsible for the highest number of deaths among Hymenoptera stings.^{3,4}

The stinging apparatus is a modified ovipositor, hence the sting ability belongs to females.³ Stinging apparatus is connected to a venom gland and used as an offensive or defensive weapon. Unlike bees, wasps can sting multiple times.⁵ The venom of wasp contains a mixture of Histamine releasing factors, enzymes, hemolysins, neurotoxins, vasodilators, vasospastic amines and Phospholipase A. Hornet stinging is a common environmental hazard in Sri Lanka. When disturbed, hornets attack in a swarm. Majority of victims recover in hospitals but some die of complications.

Clinical features of hornet stings are localized redness, swelling, and pain over the site of the wasp sting. The pain begins immediately, and gradually worsens as the redness and edema gradually worsen. The localized reaction may last 6-12 hours. A minute punctate lesion is visible at the center of the lesion where the wasp sting occurred. Patients with a mild allergic reaction may experience itching and hives. Patients with severe allergic reactions and anaphylaxis may present with throat-closing sensation, dyspnoea, chest tightness, lightheadedness, increased

anxiety, headache, nausea, abdominal cramps, palpitations, symptoms of Myasthenia gravis and optic neuropathy.⁶ Death due to anaphylaxis can occur following single sting.⁷ Envenomation occurs due to more than 20 stings and death is due to hemolysis, rhabdomyolysis and acute kidney injury.⁸ Disseminated intravascular coagulation and allergic myocardial infarctions (kounis syndrome) are the late fatal complications.⁹

A range of clinical complications ranging from nonspecific skin lesions to anaphylactic shock can occur, in a previously sensitized person, following even a single hymenopteran bite (*Vespa affinis*).¹⁰

When there is a death, external examination for wasp stings, internal examination for organ failure and blood investigations for mast cell tryptase and Ig E levels will help the diagnosis. We report a fatal case of wasp sting with 32 skin lesions.

CASE REPORT

History- A two years and nine month old girl had approached a fallen wasp net on the ground. A swarm of wasp had attacked the girl and grandmother at about 2.30 pm. At 6.30 pm girl was transferred to tertiary care hospital from local hospital. Patient died at 8.40 pm on admission to the intensive care unit.

Postmortem examination- thirty two skin lesions were seen on limbs and back. Each lesion was a black circular macule 2-3 mm in size, surrounded by an elevated erythematous margin of 0.5 to 2cm in size. Internally, bilateral pleural effusion, ascitis, dark rubbery lungs and pale kidneys with unclear cortico-medullary junctions were seen. Histology of skin showed only ectatic blood vessels.

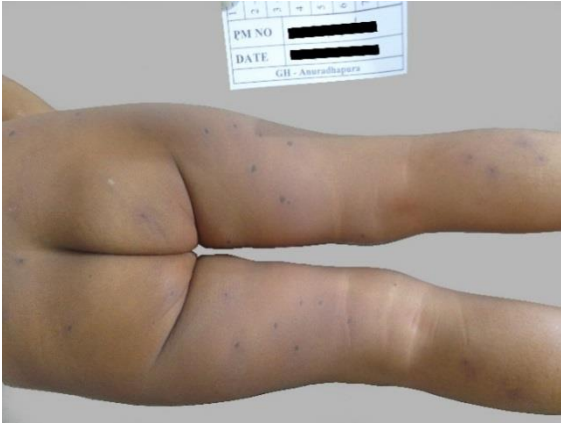

Fig. 1 : Skin lesions on legs

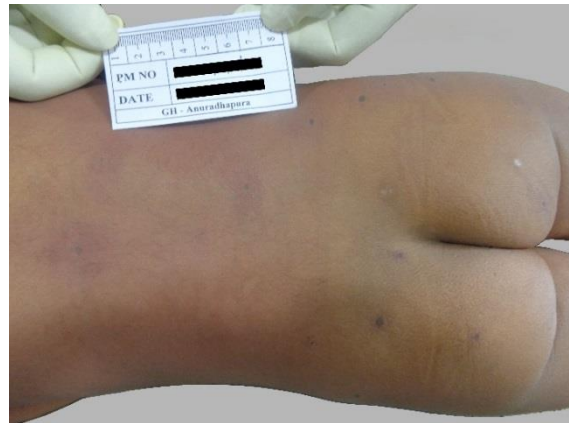
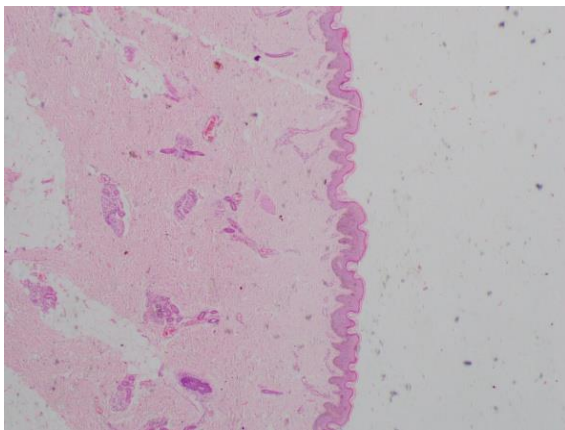
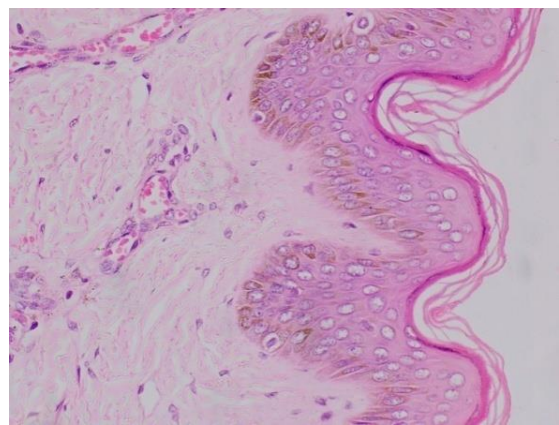


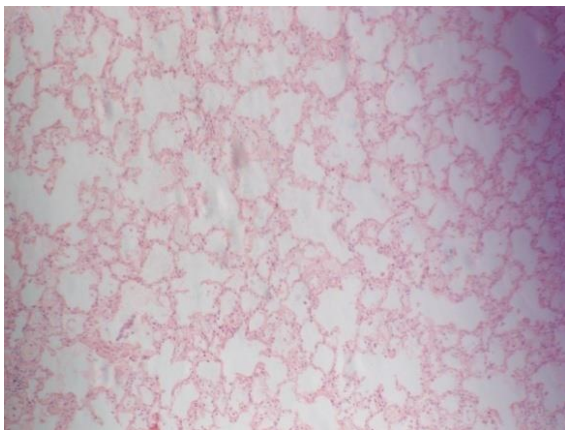
Fig. 2 : Skin lesions on back



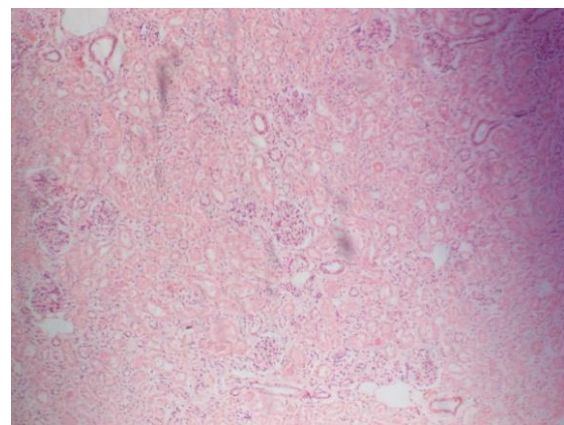
**Fig. 3: Photomicrograph of (x4)
Section of skin with ectatic blood vessels
(Hematoxylin and eosin stain)**



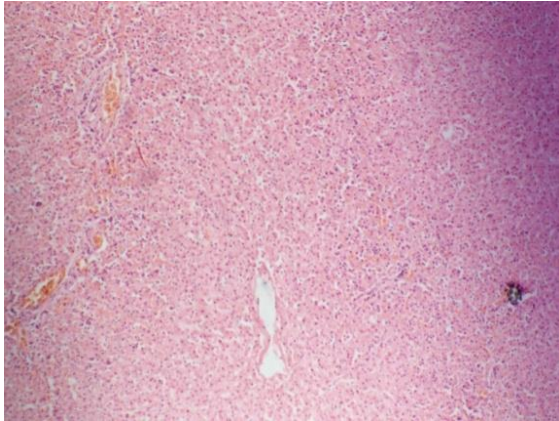
**Fig. 4: Photomicrograph of (x40)
Section of skin with no increase complement
of inflammatory sells (Hematoxylin and
eosin stain)**



**Fig. 5: Photomicrograph of Lung (x10)
Section of lung shows no pulmonary
edema evidence or micro thrombi
(Hematoxylin and eosin stain)**



**Fig. 6: Photomicrograph of Kidney Section
of kidney show no of acute tubular
necrosis (Hematoxylin and eosin stain)**



**Fig. 7: Photomicrograph of Liver (x10)
Section of liver show Congestion of
Blood vessel with no evidence of micro
thrombi (Hematoxylin and eosin stain)**

Blood was hemolysed and unsuitable for beta tryptase investigation. After exclusion of trauma and natural diseases, with the help of eye witness and medical records of local hospital, the cause of death was pronounced as anaphylaxis following wasp stings.

DISCUSSION

This is a witnessed case of wasp sting and the diagnosis was obvious for the clinicians and forensic pathologists. Because wasps are abundant in Sri Lanka and nesting close to human dwelling, stings are frequently reported on unsuspecting children and adults. Other than the history the most important clinical feature is the skin lesion. Punctuate dark color circular centre (1-2mm) with raised red circular margin (1-2cm) was observed in all 32 lesions of this case. The skin lesion was the only helpful clinical criterion for the diagnosis of wasp sting. Familiarization of skin lesion of wasp sting is important for the forensic practitioner to medically establish the diagnosis in both, witnessed deaths and also in the investigations of unwitnessed deaths recovered from jungles to exclude the possibility of wasp sting. Internal

examination will be helpful to establish immediate cause of deaths such as multi organ failure due to anaphylaxis, acute pulmonary oedema, cardiotoxicity and acute kidney injury due to envenomation.⁶ Histology of skin lesions usually shows ectatic blood vessels and inflammatory cell infiltration. Absence of inflammatory cells in this case may be due to early death before cell migration.

To confirm anaphylaxis following wasp sting, needs blood investigations; but hemolysis would be an obstacle, as in this case. Therefore preservation of antemortem blood sample and early collection of postmortem blood samples should be a routine practice in all suspected deaths due to anaphylaxis. Failure of the medical management in this case may be due to acuteness and severity of the allergic reaction as well as the younger age.

CONCLUSION

Familiarization of skin lesions of wasp sting is important for forensic practitioners. Preservation of antemortem blood sample and early collection of postmortem serum sample after centrifuging blood should be a routine practice in all suspected deaths due to anaphylaxis.

REFERENCES

1. Akre RD, Reed HC: Ants, wasps and bees. Medical and veterinary Entomology. Edited by: Garry M, Lance D. 2002, London: Academic Press, 383-408.
2. Goulet H, Huber JT: Hymenoptera of the World: An Identification Guide to Families. 1993, Ottawa: Canada Communication Group.
3. Kularatne SAM, Gawarammana IB, De Silva PHJG: Severe multi-organ dysfunction following multiple wasp (*Vespa affinis*) Stings. CMJ. 2003, 48: 146-147.
4. Kularathne K, Kannaagara T, Jayasena A, et al. Fatal acute pulmonary oedema and acute renal failure following wasp/hornet sting in Sri Lanka: two case reports. Journal of medical case reports. 2014 June 13. https://www.researchgate.net/publication/263100451_Fatal_acute_pulmonary_oedema_and_acute_renal_failure_following_multiple_wasp_hornet_Vespa_affinis_stings_in_Sri_Lanka_Two_case_reports
5. Pick T: Wasp kinins and kinin analogues. Animal Toxins; Facts and Protocols. Edited by: Rochat H, Martin MF. 2000, Basel: Birkhauser, 100-103.
6. Maltzman JS, Lee AG, Miller NR: Optic neuropathy occurring after bee and wasp sting. Ophthalmology 2000, 107(1):193-195.
7. Sharmila R, Chetan G, Narayan P, Srinivasan S. Multiorgan dysfunction syndrome following single wasp sting. The Indian Journal of paediatrics. 2007 Dec; 74(12) 1111-2
8. Vetr RS, Visscher PK, Camzine S. Mass envenomation by honey bees and wasps. Western Journal of Medicine. 1999 Apr; 170(4): 223-227 (PMID: PMC1305553)
9. George P, Pawar B, Calton N, Mathew P. Wasp sting: An unusual fatal outcome. Saudi Journal of kidney diseases and transplantation. 2008; 19(6) 969-972
10. Gunasekara WDVN, Ratnatunga NVI, Abeygunawardana AS: Acute renal failure following multiple wasp bites. Sri Lanka J Child Health 2007, 36:67-68.13.