

SEX DETERMINATION BY MANDIBULAR RAMUS - A DIGITAL PANORAMIC STUDY -

Ranaweera W.G.P.E.¹, Chandrasekara C.M.C.T.K.², Haputhanthiri H.D.S.³,
Padma De Silva⁴ & Herath L.H.M.I.M.⁵

¹Nawaloka Premier Centre, Sri Lanka

²Nawaloka Hospital PLC, Sri Lanka

³Teaching Hospital, General Sir John Kotelawala Defence University, Sri Lanka

⁴National Dental Hospital, Ward Place, Colombo, Sri Lanka

⁵Department of Radiography and Radiotherapy, Faculty of Allied Health Sciences, General Sir John Kotelawala Defence University, Sri Lanka

Corresponding Author: Ranaweera W.G.P.E

E-mail: erangikaranaweera615@gmail.com

 <https://orcid.org/0000-0002-4885-0501>

ABSTRACT

Sex determination becomes the main part in the procedure of identification of a person by forensic investigator in a case of mishaps, chemical and nuclear bomb explosions, natural disasters, crime investigations and ethical studies. In human remains, next to pelvis, mandible is used as the best key for the sex determination. Aim of the study was to evaluate the sex dimorphism in measurements of mandibular ramus by using orthopantomographic (OPG) images. The retrospective study was conducted using digital OPG images of 175 males and 175 females between age group of 20 and 60. The measurements were taken by using tools fetched with “APL software v8.1”. Discriminant analysis was done using SPSS (version 23) software. Statistically significant relationships were found between sex and maximum ramus breadth ($p=0.000$), minimum ramus breadth ($p=0.024$), condylar height ($p=0.000$), projective height ($p=0.000$), coronoid height ($p=0.000$). Furthermore, condylar height showed highest sex differentiation in its measurements (Wilks’ lambda = 0.659), followed by Projective height. The study revealed higher identification rates for males (77.1%) and females (73.7%) with a total accuracy rate of 75.4% (Table 5). These results justify that the above said parameters can produce reliable results in sex determination from OPG. According to our results there is a relationship between maximum ramus breadth, minimum ramus breadth, condylar height, projective height, coronoid height. From all the parameters condylar height was found to be more reliable to determine sex.



All articles in Sri Lanka Journal of Forensic Medicine, Science & Law are licensed under the terms of the Creative Commons Attribution-Non Commercial 4.0 International License.

INTRODUCTION

Sex determination is a main part of the forensic odontology and its essential when the evidences are not sufficient enough to identify the dead body. Sex determination becomes the main part in the procedure of identification of a person by forensic investigator in a case of mishaps, chemical and nuclear bomb explosions, natural disasters, crime investigations and ethical studies (Ayesha *et al.*, 2015).

Identification of the skeletal remains is a very important step in medico-legal investigations. Most of the time parts of the pelvis and skull are used for the sex determination. Presence of a dense layer of compact bones makes it durable and well preserved than many other bones (David *et al.*, 2012). In human remains, next to pelvis, mandible is used as the best key for the sex determination (Jambunath *et al.*, 2016).

Skeleton has always aided in genetics, anthropological, odontological and forensic investigation of living and non-living individuals (John *et al.*, 1998). So far in sex determination pelvis region and the skull bones have been played a major role.

When the entire adult skeleton is available for analysis, sex can be determined up to 98% accuracy (Krogman *et al.*, 1986), but in a vast disaster or fatal incident where the loss of the pelvic region, the skull is playing a vital role in sex determination. Skull is the most dimorphic and easily sexed portion of skeleton after pelvis providing accuracy up to 92%. But in cases where intact skull is not found mandible may play a vital role in sex determination as it is the most dimorphic, largest and strongest bone of the skull (David *et al.*, 2012).

Mandible is a bone which forms an articulation with the cranium. It is the one and only bone in the entire skull which is not fused with its adjacent cranium bones

via sutures. It also articulates with the neurocranium via the temporal bone, forming the temporomandibular joint (TMJ). Mandible is a single bone and it is symmetrical on both sides and aid in movements of the mouth and chewing process of the foods. The lower set of teeth in the mouth is rooted in to this bone and muscles are attached to it to facilitate the movements of the bone. Some of the muscles that mandibular ramus is surrounded are the masseter, the temporalis, the medial pterygoid, and the lateral pterygoid (Healthline.com, 2015).

There are several types of dental X-rays. Mainly it divides in two categories as extra oral and intra oral. Bitewing radiography, Periapical radiography and occlusal radiography are known as the intra oral radiography. OPG, lateral oblique projection and cephalograms comes under the extra oral radiography.

Orthopantomography (OPG) is a technique which is used to image upper and lower jaws of the human body. It's also known as rotational panoramic radiography, dental panoramic tomography and panoral. Panoramic equipment is based upon a simultaneous rotational movement of the tube head and the film cassette in equal but opposite directions around the patient's head, which remains stationary. OPG images are taken for orthodontic assessment of the absence and presence of the teeth, to detect fractures of the mandible, to assess large pathological lesions such as tumor and cysts and to assess third molar before surgery.

The panoramic radiograph is one of the complementary exams most required by dentists for diagnostic purposes. Among all the periapical images, OPG has been playing an important role in dental radiography. OPG is popular due to the wide visualization of dental arches, mandibular and maxillary bones. Most of the extra oral radiographic equipment does not provide exposure settings compatible

with unique situation. This can be easily overcome by using digital OPG machine as well as OPG manipulate the image for quality enhancement (Beaini *et al.*, 2016).

Primarily, the present study was planned to determine the sex using mandibular ramus with the help of maximum ramus breadth, minimum ramus breadth, condylar height, projective height and coronoid height measured on OPG image. Specifically, to assess the usefulness of mandibular ramus in sex determination and to evaluate the most significant mandibular ramus parameter to determine sex in Sri Lankan population.

MATERIALS AND METHODOLOGY

The study was conducted in Army hospital, Narahenpita, Sri Lanka from 1st of July to 30th of November 2017. The study sample includes 175 OPG images of male patients and 175 OPG images of female patients among the age group of 20–60 years. VERA VIEW POCS X-550 OPG machine was used to take the OPG images.

Images of female and male patient between the age group of 20-60 ages were only taken for the study.

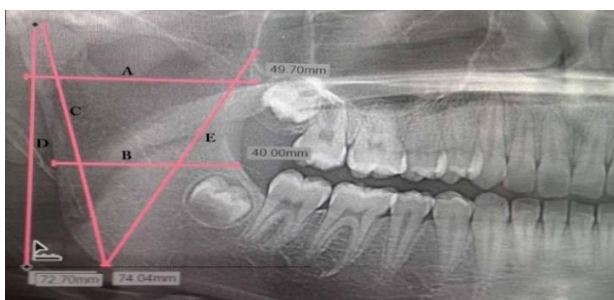


Figure 1: Measurements of the Mandible

Blurred images, images which were taken from the patients who had not a natural permanent dentition and OPG images of patients with any syndromes like: cleft lip, palate or other craniofacial pathology were rejected.

Technically erroneous OPG images according to the standard imaging criteria were also excluded. All OPG images have been taken by a one qualified radiographer.

This cross-sectional study mainly focused on the determination of the sex by the measurements of mandibular ramus. Each measurement was rechecked by all the researchers. “APL software V8.1” software was used to measure the parameters which were saved in the database.

As illustrated in [Figure 1](#), maximum ramus breadth, minimum ramus breadth, condylar height, projective height and coronoid height were measured on the OPG image. 137.9% magnified image will be used to measure the parameters. The most significant parameter for the determination of the sex has been assessed statistically. SPSS software (version 23) was used for the statistical analyzing purposes.

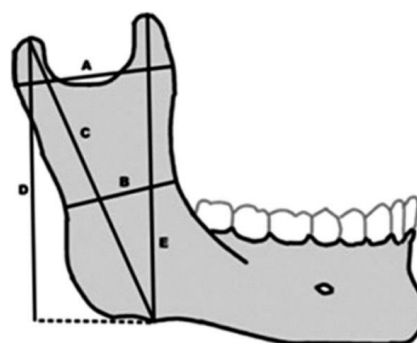


Figure 2: Lateral view of the Mandible

- A — Maximum ramus breadth: Distance between most anterior and line connecting most posterior part of condyle and angle of jaw.
- B — Minimum ramus breadth: Distance between smallest anterior to posterior of ramus.
- C — Condylar height: Height of ramus from most superior part on condyle to the tubercle or most protruding portion of the inferior border of the ramus.
- D — Projective height: Distance between highest part of condyle and lower margin of mandible.
- E — Coronoid height: Projective distance between coronion to lower margin of mandible.

RESULTS

Table 1: Age descriptive statistics

Age	Range		Mean		Skewness	Kurtosis
	Minimum	Maximum	Statistics	Std.error		
Age	20	58	30.01	0.446	1.180	1.004

With regards to age groups, highest number of male patients (112/350, 32%) were aged between 20-30 years and highest number of female patients (109/350, 31.14%) were aged between 20-30 years while the minimum number of male patients (3/350, 0.86%) were aged between 51-60 and minimum number of female patient were aged between 51-60 (Figure 2).

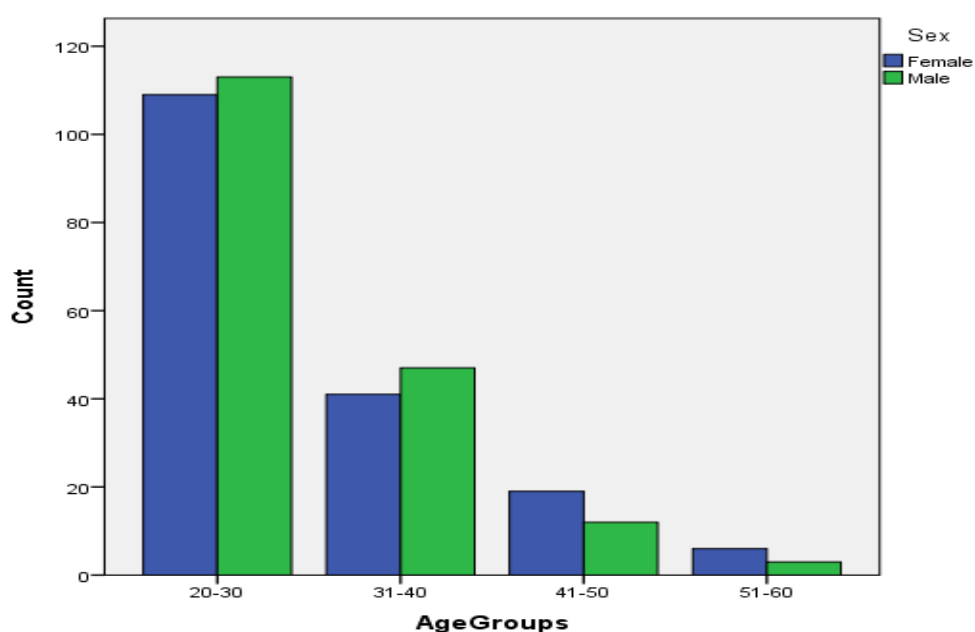


Figure 3: Age distribution with number of patients

Distribution of the age range were tested by normality test and the data were not normally distributed ($p < 0.05$) as shown in Table 2.

Table 2: Tests of normality for age

Age	Tests of Normality					
	Kolmogorov-Smirnov			Shapiro-Wilk		
	Statistic	Df	Sig.	Statistic	Df	Sig.
Age	.154	350	.000	.893	350	.000

Measurements of maximum ramus breadth, minimum ramus breadth, condylar height, projective height and coronoid height were taken for every patient from the hospital data base. Distributions of these measurements were tested by normality test and determined that data were normally distributed. ($p > 0.05$).

Table 3: Tests of normality for mandibular ramus measurements

	Sex	<i>p</i> -value
Maximum ramus breath (mm)	Female	0.100
	Male	0.213
Minimum ramus breath (mm)	Female	0.195
	Male	0.053
Condylar height (mm)	Female	0.006
	Male	0.619
Projective height (mm)	Female	0.720
	Male	0.637
Coronoid height	Female	0.765
	Male	0.414

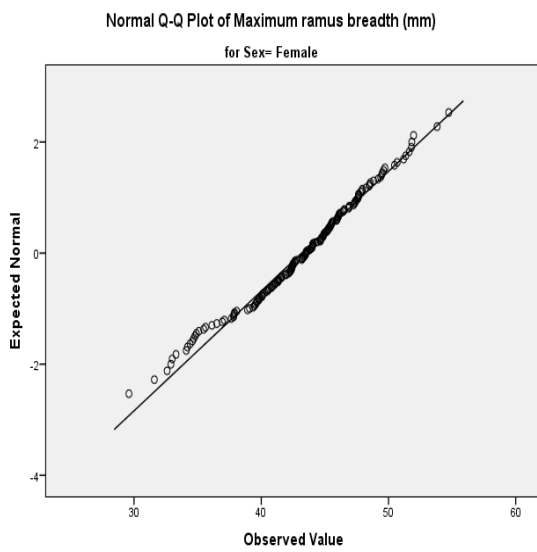


Figure 3: Normal Q-Q plot of Maximum ramus breadth (mm) for female

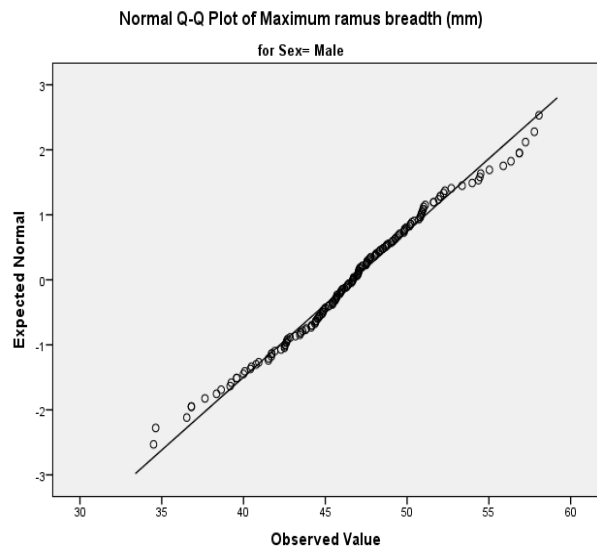


Figure 4: Normal Q-Q plot of Maximum ramus breadth (mm) for male

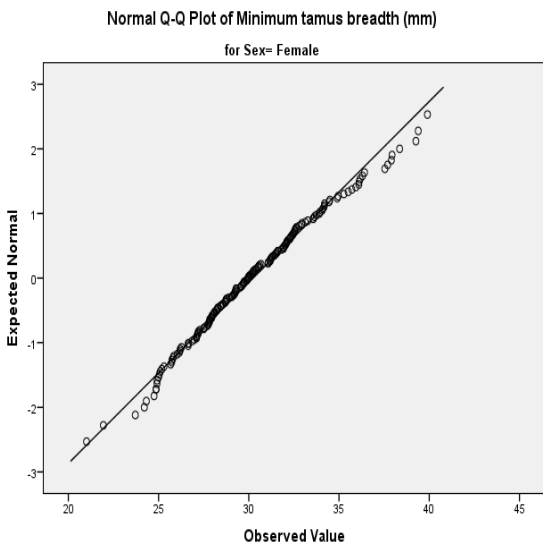


Figure 5: Normal Q-Q plot of Minimum ramus breadth (mm) for female

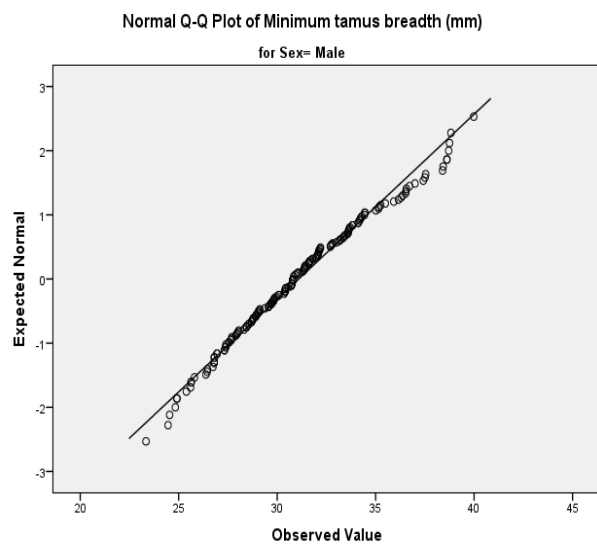


Figure 6: Normal Q-Q plot of Minimum ramus breadth (mm) for male

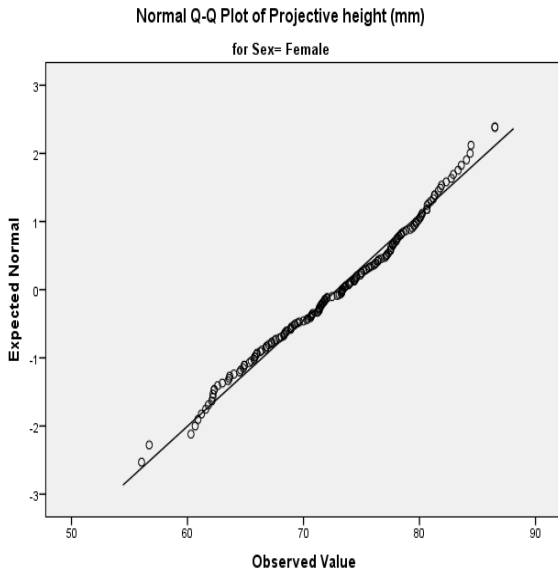


Figure 7: Normal Q-Q plot of Projective height (mm) for female

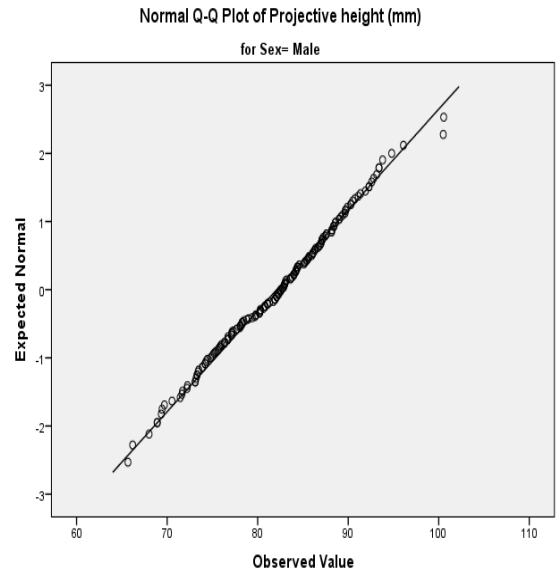


Figure 8: Normal Q-Q plot of Projective height (mm) for male

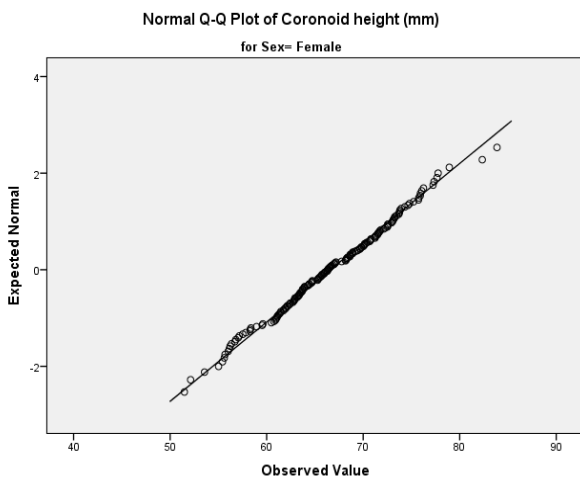


Figure 9: Normal Q-Q plot of Coronoid height (mm) for female

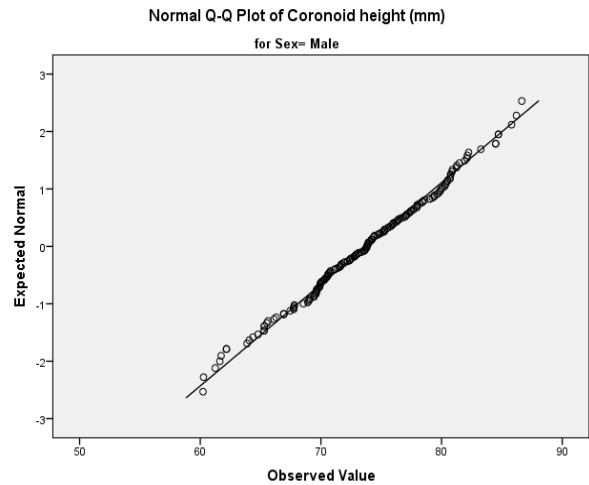


Figure 10: Normal Q-Q plot of Coronoid height (mm) for male

All the five measurements were subjected to statistical analysis. There is a specific difference between all five mandibular ramus measurements at 5% level of significance. (Maximum ramus breadth $p=0.000$), (minimum ramus breadth $p=0.024$), (condylar height $p=0.000$), (projective height $p= 0.000$), (coronoid height $p=0.000$).

Table 4: For mean and std deviation of coefficient in original sample

	Sex	N	Mean	SD	Wilks` Lambda	p- value
Maximum ramus breadth (mm)	Female	350	43.17	4.637	0.870	0.000
	Male	350	46.68	4.461		
Minimum ramus breadth (mm)	Female	350	30.24	3.570	0.985	0.024
	Male	350	31.09	3.465		

Condylar height (mm)	Female	350	75.59	6.404	0.659	0.000
	Male	350	85.21	6.989		
Projective height (mm)	Female	350	72.89	6.404	0.671	0.000
	Male	350	82.10	6.759		
Coronoid height (mm)	Female	350	66.60	6.092	0.730	0.000
	Male	350	73.73	5.649		

A statistically significant difference was observed in the mean values of maximum ramus breadth, minimum ramus breadth, condylar height, projective height, coronoid height. The results show a definite dimorphic feature in these measurements,

which help in sex differentiation using these parameters. Of all the parameters the condylar height showed highest sex differentiation in its measurements (Wilks' lambda = 0.659), followed by projective height (Table 4).

Table 5: Test of Equality of group means

	Maximum ramus breadth (mm)	Minimum ramus breadth (mm)	Condylar height (mm)	Projective height (mm)	Coronoid height (mm)
Wilks' Lambda	0.870	0.985	0.659	0.671	0.730

Discriminant analysis was done using sex as a grouping variable and maximum ramus breadth, minimum ramus breadth, condylar height, projective height, coronoid height as independent variables and the discriminant equation was obtained for sex determination.

$D_{\text{female}} = 0.947 \text{ Maximum ramus breadth} + 1.197 \text{ Minimum ramus breadth} + 0.253 \text{ Condylar height} + 0.584 \text{ Projective height} + 0.976 \text{ Coronoid height} - 102.586$

$D_{\text{male}} = 1.030 \text{ Maximum ramus breadth} + 1.126 \text{ Minimum ramus breadth} + 0.325 \text{ Condylar height} + 0.665 \text{ Projective height} + 1.071 \text{ Coronoid height} - 122.882$. "D" is the discriminant score.

The study revealed higher identification rates for males (77.1%) and females (73.7%) with a total accuracy rate of 75.4% (Table 5). These results justify that the above said parameters can produce reliable results in sex determination from OPG.

In this study the sectioning point was found to be 0 (zero). Values greater than this sectioning point indicate male and the values lesser than sectioning point indicate female.

Table 6: Prediction Accuracy

	Predicted male	Predicted female	Total
Male	135	40	175
	77.1%	22.9%	
Female	46	129	175
	26.3%	73.7%	

DISCUSSION

Sex determination is playing an extremely important role in identification of an individual. This study was aimed to determine the sex by mandibular ramus. 175 OPG images of males and 175 OPG images of females were selected for the study from the data base of the Army Hospital, Narahenpita, Sri Lanka. The sample was consisted of total number of 350 images of patients among 20-60 years of age.

Mandible rami can be used for sexual dimorphism as it is a reliable tool for gender prediction.

All the mandibular ramus measurements (maximum ramus breadth, minimum ramus breadth, condylar height, projective height and coronoid height) were subjected to the discriminant analysis.

According to the study, the measurements (maximum ramus breadth, minimum ramus breadth, condylar height, projective height and coronoid height) were shown a significant sex difference between both genders. Condylar height was showed as the most significant variable for the Sri Lankan population (Table 5).

A study conducted by Saini et al., 2009 showed that coronoid height possessed the best potential for sex determination of Indian people, but according to the current study best potential sex predicting parameter for the Sri Lankan population is condylar height (Table 5).

According to a research conducted in India (More et al., 2017) has shown that each of the five variables measured on mandibular ramus were statistically significant ($p < 0.05$). The current study also showed that there is a significant relationship between sex and the mandibular ramus measurements (maximum ramus breadth, minimum ramus breadth, condylar height, projective height and coronoid height).

Furthermore, it has shown that maximum ramus breadth and the projective ramus height has the highest sexual dimorphism, which did not stimulate with the results of the current study. The condylar height has the highest sexual dimorphism according to the current study. The study has got 68% of accuracy rate for males, 70% accuracy rate for females and total accuracy rate of 69% and also another study conducted by Jambunath et al. has shown that the sexual dimorphism can be found from the mandibular ramus up to an accuracy level of 72%. According to the current study there was a 77.1% of accuracy level for males, 73.7% accuracy level for females with a total accuracy rate of 75.4% (Table 6).

CONCLUSION AND RECOMMENDATIONS

OPG has been proven to be a valuable tool for the determination of morphological dimensions of the mandible ramus. Through the use of mandibular ramus parameters such as maximum ramus breadth, minimum ramus breadth, condylar height, projective height and coronoid height, sex can be determined. The implications of such correlations have

numerous applications in the fields of forensic identification and orthodontic analysis.

According to our overall findings, significant relationship between sex and mandibular ramus measurements were found. ($p < 0.05$). Similarly, condylar height showed a marked significant difference (Wilks' lambda = 0.659) than maximum ramus breadth, minimum ramus breadth, projective height, coronoid height. From the results obtained within the Army hospital population; Males had a larger condylar height than females.

The results of this study will be helpful for medico-legal practices in Sri Lanka since this is the first research study done on sex determination using mandibular ramus for a Sri Lankan population.

Finally, further studies are encouraged to conduct on a large scale in various population groups to estimate the significance of mandibular ramus measurements in sex determination.

ACKNOWLEDGEMENT

We would like to express our sincere gratitude to our research supervisor, Dr S.Padma Silva, Consultant Oral Maxillofacial surgeon, Dental Institute of Colombo, Sri Lanka, for her kind guidance throughout the study.

Further we would like to thank our research co-supervisor Ms. L.H.M.I.M. Herath, Lecturer of Department of Radiography and Radiotherapy, Faculty of Allied Health Sciences, General Sir John Kotelawala Defence University.

We would like to extend our gratitude to Mr. Prageeth Ranga Dissanayake for his immense support.

Our special appreciation goes to staff members of the Army Hospital,

Narahenpita for their contribution towards the success of this research.

REFERENCES

1. Ammanagi RA, Byahatti SM, Samantha K, Sarang CK, Shivpuje P, Tantradi P. Sex determination by mandibular ramus: A digital orthopantomographic study. Journal of forensic dental sciences [Internet]. 2016 [cited 2017 January 23];8(2):95–98. Available from: <http://www.jfds.org>
2. Balsaraf S, Chole RH, Gadbail AR, Gondivkar S, Patil RN, Yuwanathi MB. Association of mandible anatomy with age, gender and dental status, ISRN Radiology [Internet]. 2013 [cited 2017 January 23]:1-4. Available from: <http://www.hindawi.com/journals/isrn/2013/453763/>
3. Beshlewy DME, Taleb NSA. Mandibular ramus and gonial angle measurements as predictor of sex and age in an Egyptian population sample: A digital panoramic study. Journal of Forensic research [Internet]. 2015 [cited 2017 January 23]; 6 (5):1-7. Available from: <http://www.dx.doi.org/10.4172/2157-7145.1000308>
4. Bhagwatkar T, Bhondey A, Chathurvedi S, Dhengar Y, Palve D, Thakur M. Sex determination by using mandibular ramus- A forensic study. Journal of advanced medical and dental sciences research [Internet]. 2016 [cited 2017 January 23];4(2):1-6. Available from: <http://www.wjamdsr.com>
5. Chatra L, Hameed S, Kushraj T, Prabhu RV, Rao K, Shenai P, Shetty P, Rupa KR. Gonial angle and ramus height as sex determinants: A radiographic pilot study. Journal of cranio-Maxillary Diseases [Internet]. 2015 [cited 2017 January 23];4(20):111-116. Available from: <http://www.craniomaxillary.com>
6. Chennoju SK, Kumar BN, Pavani K, Praveen KNS, Ramesh T, Reddy RS. Morphometric analysis of mandible for sex determination – A retrospective study. International journal of science and research methodology [Internet]. 2016 [cited 2017 January 23]; 4(3):115-122.

- Available from: <http://www.ijrsm.humanjournals.com>
7. David MP, Indira AP, Markande A. Mandible ramus: An indicator for sex determination- A digital radiographic study. *Journal of forensic dental sciences* [Internet]. 2012 [cited 2017 January 23];4(2):58–62. Available from: <http://www.jfds.org>
 8. Deepthi DC, Kumar BS. A digital radiographic study for gender predication using mandibular indices. *International journal of science and research* [Internet]. 2016 [cited 2017 January 23];5(5):1490-1493. Available from: www.ijsr.net
 9. Jambunath V, Govindraju P, Balaji P, Poornima C, Latha S, Former. Sex determination by using mandibular ramus and gonial angle- A preliminary comparative study. *International Journal of Contemporary Medical Research* [Internet]. 2016 [cited January 25];3(11):2454-7379. Available from: <http://www.ijcmr.com>
 10. Kartheeki B, Lakshmana N, Nayyar AS, Sindhu YU. Accuracy of mandibular rami measurements in prediction of sex. *Achieves of medicine and health sciences* [internet]. 2017 [cited 2017 December 19];5(1):50-54. Available from: <https://goo.gl/xXSFkd>
 11. Leversha J, McKeough G, Myrteza A, Sholapurkar A, Wakefiled HS, Welsh J. Age and gender correlation of gonial angle, ramus height and bigonial width in dentate subjects in a dental school in Far North Queensland. *Journal of clinical and experimental dentistry* [Internet]. 2016 [cited 2017 January 23];8(1):49–54. Available from: <http://www.ncbi.nlm.nih.gov/pmc/articles/PMC4739368>
 12. Muskaan A, Sarkar S. Mandible an indicator for age and sex determination using digital orthopantomogram, *Scholars Journal of Dental Sciences*[Internet]. 2015 [cited 2017 January 23];2(1):82-95 Available from: <http://www.saspublisher.com>
 13. Mandible Anatomy, Definition & Function –Body Maps. Healthline [Internet]. 2017 [cited 2017 January 23]. Available from: <http://www.healthline.com/human-body-maps/mandible>
 14. Rai RK, Saini V, Shamal SN, Singh TB, Srivastava R, Tripathi SK. Mandibular ramus: An indicator for sex in fragmentary mandible. *Journal of forensic sciences* [Internet]. 2010 [cited 2018 January 01];56(S1):S13- S16. Available from: <https://goo.gl/h2Mfwh>
 15. Saikiran CH, Ramswamy P, Santosh N, Satish A, Smitha B, Sudhakar S. Can gonial measurements predict gender? A prospective analysis using digital panoramic radiographs. *Forensic research and criminology international journal* [Internet]. 2016 [cited 2017 December 22];3(2):89. Available from: <https://goo.gl/SHi2U2>
 16. Sujatha BK. Gender determination in panoramic radiographs, utilizing mandibular ramus parameters: A cross sectional study. *Journal of dental research and review* [Internet]. 2017 [cited 2018 January 01];4(2):32-35. Available from: <https://goo.gl/uMCcTi>
 17. More CB, Vijayavargiya R, Saha N. Morphometric analysis of mandibular ramus for sex determination on digital orthopantomogram. *Journal of forensic dental science* [Internet]. 2017 [cited 2017 December 23];9(1):1-5. Available from: <https://goo.gl/4H2YF2>
 18. Ramakrishnan K, Sharma S, Sreeja C, Pratima DB, Aesha I, Vijayabanu B. Sex determination in forensic odontology: A review. *Journal of Pharmacy & Bioallied Sciences* [Internet]. 2015 [cited 2017 December 23];7(2):S398–S402. Available from: <http://doi.org/10.4103/0975-7406.163469>