

P-C2.

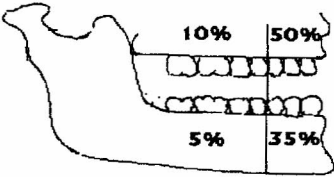
ADENOMATOID ODONTOGENIC TUMOUR (AOT) IN THE POSTERIOR MANDIBLE WITH UNUSUAL PRESENTATION

B.R.P.L. GUNATILEKA, B.R.R.N. MENDIS, E.A.P.D. AMARATUNGA
AND A. RANASINGHE*

*Department of Oral Pathology, Faculty of Dental Sciences, University of Peradeniya,
and * Dental Institute, Colombo*

The WHO classifies the AOT as an odontogenic tumour, derived from the epithelial components of the developing tooth germ. The recent literature suggests that the odontogenic ectomesenchyme plays a part in the pathogenesis of this tumour. The early cases have been reported as glandular adamantinoma, pseudo-adenoma adamantum or adenoameloblastoma. Philipson named the tumour Adenomatoid Odontogenic Tumour. Some authors however believe that the AOT is a hamartomatous lesion. The AOT accounts for about 0.1% of all tumours and cysts seen in the jaws. It comprises about 3% of all odontogenic tumours.

Case Report: A 13 years old girl presented with pain in relation to the $\overline{6}$. On examination there was pain on percussion and exaggerated response to pulp testing with heated G.P. Radiologically, a radiolucent lesion could be seen in the right side of the mandible extending from $\overline{4}$ to unerupted $\overline{8}$ region. An incisional biopsy was done. The clinical diagnosis was aneurysmal bone cyst. Microscopically, the connective tissue contained many proliferating epithelial islands arranged in the form of islands, cords and knots. There was also evidence of abnormal calcification in the connective tissue. Also the lesion seems to merge with the oral epithelium. Myxomatous tissue with irregular calcification could also be seen. These histopathological features are consistent with that of an AOT in relation to the 87654 | region. The definitive surgery was done and the unerupted $\overline{8}$ was removed with the lesion. The patient is being followed up at the Dental Institute, Colombo. What makes this case unusual is summarized below.

	AOT in general	Present case
Site		<ul style="list-style-type: none">• occurred in the posterior region of the mandible
Clinical features	<ul style="list-style-type: none">• commonly occur in anterior part of the jaws (85%)• usually present as a swelling• asymptomatic	<ul style="list-style-type: none">• there was no swelling• present with pain in relation to $\overline{6}$
X-ray	<ul style="list-style-type: none">• usually follicular and central lesion associated with an embedded tooth• radiolucent, with distribution of small opaque foci.	<ul style="list-style-type: none">• extra follicular and no connection to the impacted tooth• radiolucent but with no opaque foci seen.